



Bekkensmerter hos kvinner: Hvilken rolle kan sacroiliacal leddet og leddnære strukturer spille?

Christian Fossum, D.O.

Førstelektor

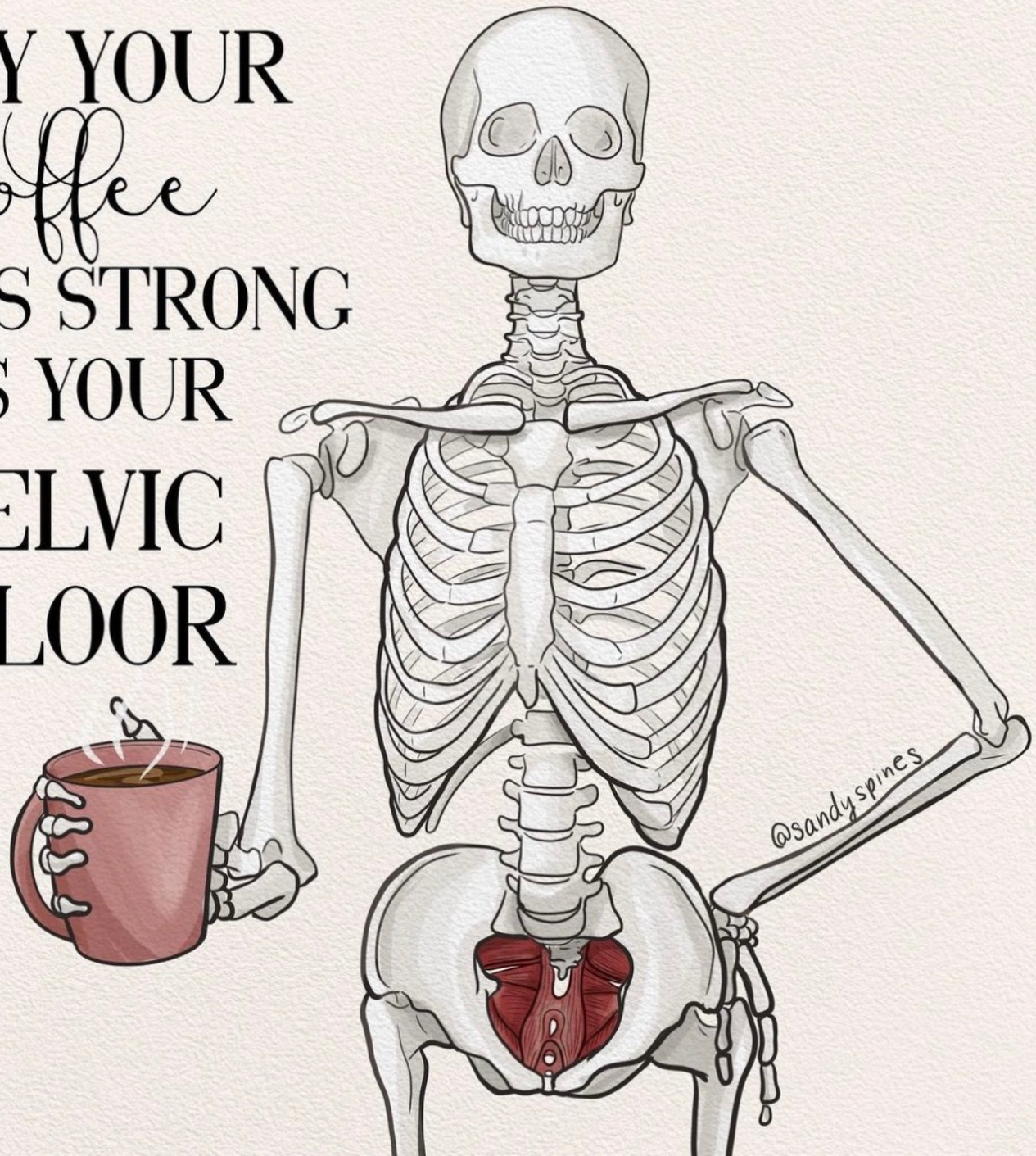
School of Health Sciences

Kjære deltaker på Kvinnehelsekonferansen

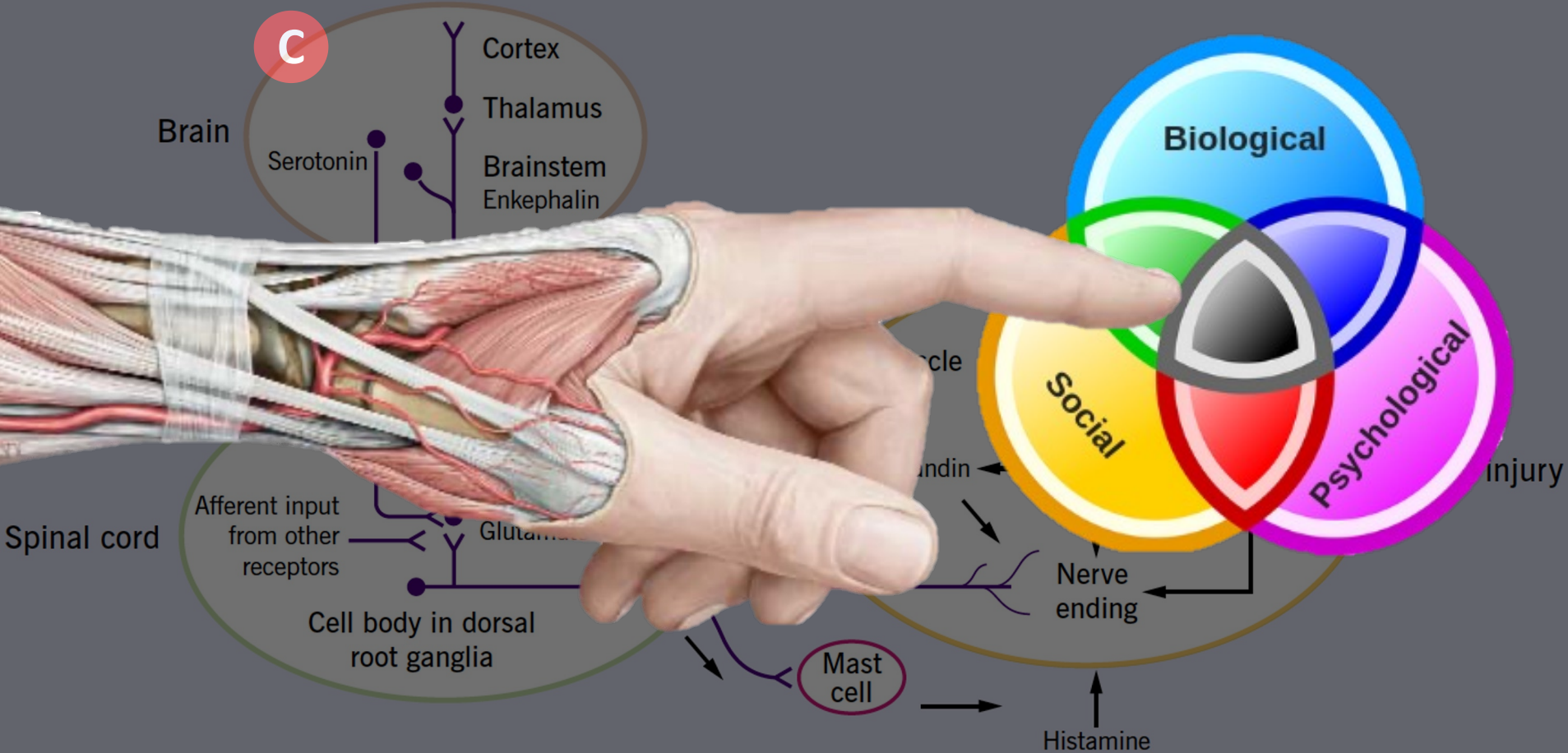
- Her finner du materialet jeg presenterte
- Det jeg har lagt til denne PDF – filen er
 - Mulige smertebilder fra SI – Leddsregionen
 - Her har jeg lagt til litt tekst for å sammenfatte relevansen til overlappende smertebilder man kan møte hos pasienten
 - Kort om vaskularisering av leddet da Svangerskap ofte beskrives som risikofaktor for infeksjon i leddet (Bakteremi). Selv om det er sjeldent, så prøver jeg å illustrere hvordan leddet står i forbindelse med systemisk sirkulasjon, da spesielt gjennom det venøse systemet
- Håper dette kan være av nytte for deg i din kliniske hverdag i både undersøkelse, behandling og samtale med de pasientene vi er så heldige at vi kan følge opp gjennom deres svangerskapsreise

Hilsen Christian

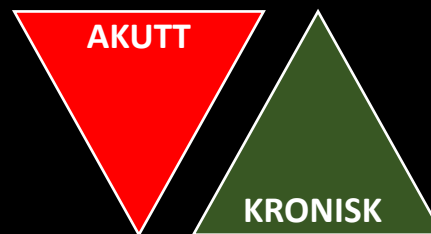
MAY YOUR
coffee
BE AS STRONG
AS YOUR
PELVIC
FLOOR



Patofysiologi Muskel- og Skjelettsmerter

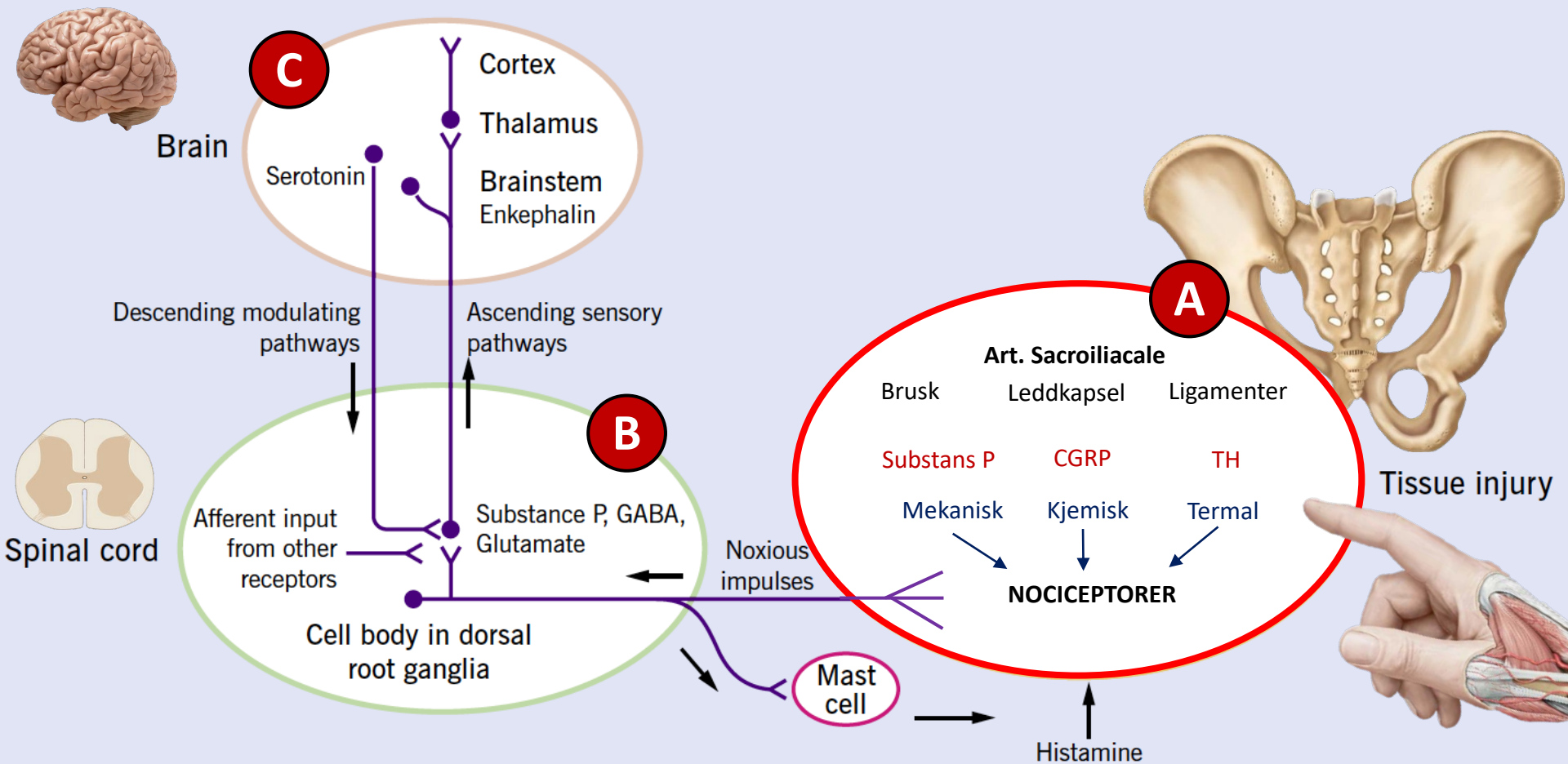


- A. Perifer Sensitivisering
- B. Sentral Sensitivisering
- C. Kognitiv Sensitivisering

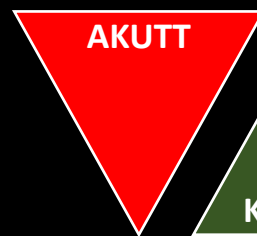


Smerteopplevelsen med sine sensoriske, emosjonelle og affektive komponenter

Patofysiologi Muskel- og Skjelettsmerter

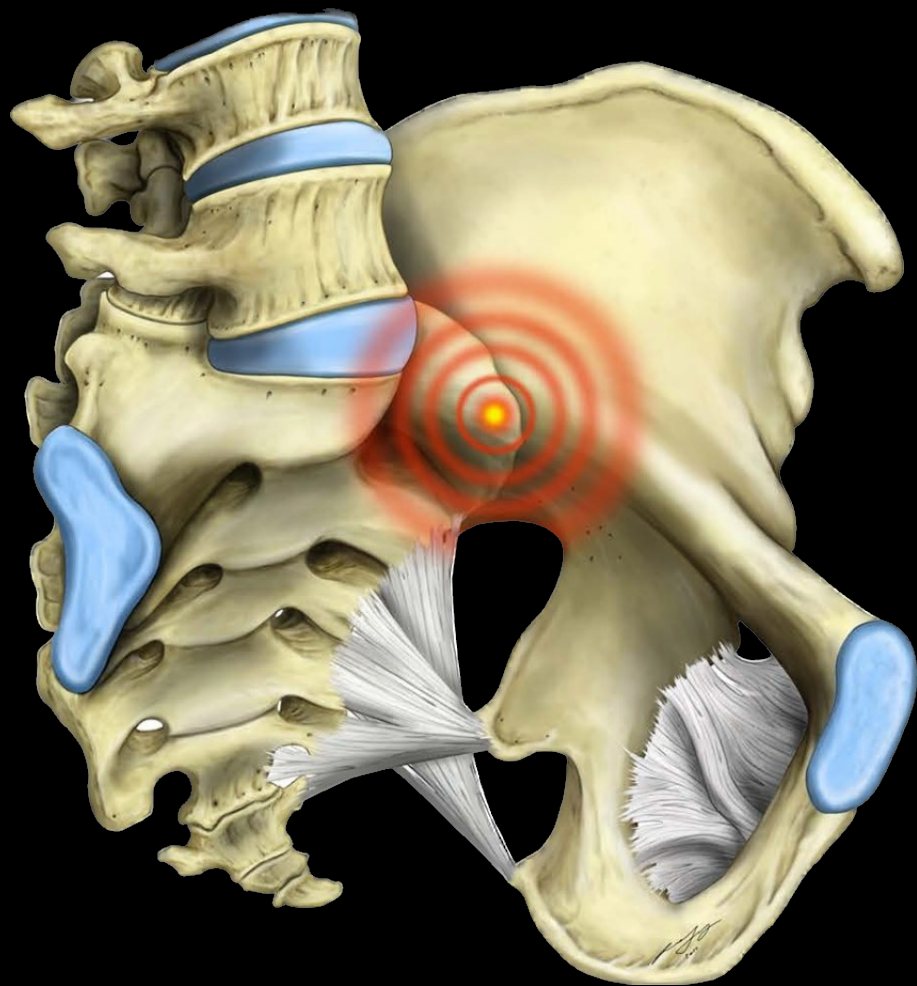


- A. Perifer Sensitivisering
- B. Sentral Sensitivisering
- C. Kognitiv Sensitivisering



Smerteopplevelsen med sine sensoriske, emosjonelle og affektive komponenter

Sacroiliacal Leddet (SIL): Også kjent som...



- Det obskure leddet
 - Det irrasjonelle leddet
 - Det enigmatiske leddet
-

Gjennom vår manglende forståelse for dette leddkomplekset, koblet med usikkerheten rundt diagnostisering og effektiv terapi, har vi kanskje endt opp med å trivialisere den betydningen denne regionen kan spille i pasientens kliniske presentasjon

Sacroiliac Leddet (SIL): Utfordringen



“If the evolution of sacroiliac joint pain treatment were measured on a clock, the time would be no later than 12.01AM. Our state of knowledge on the etiology, diagnosis and treatment of the condition is in its earliest stages of infancy”

Cohen SP. Epidemics, evolution, and sacroiliac joint pain. *Reg Anesth Pain Med.* 32(1): 3-6, 2007

Sacroiliacal Leddet (SIL): Utfordringen



“If the evolution of sacroiliac joint pain treatment were measured on a clock, the time would be no later than 12.01AM. Our state of knowledge on the etiology, diagnosis and treatment of the condition is in its earliest stages of infancy”

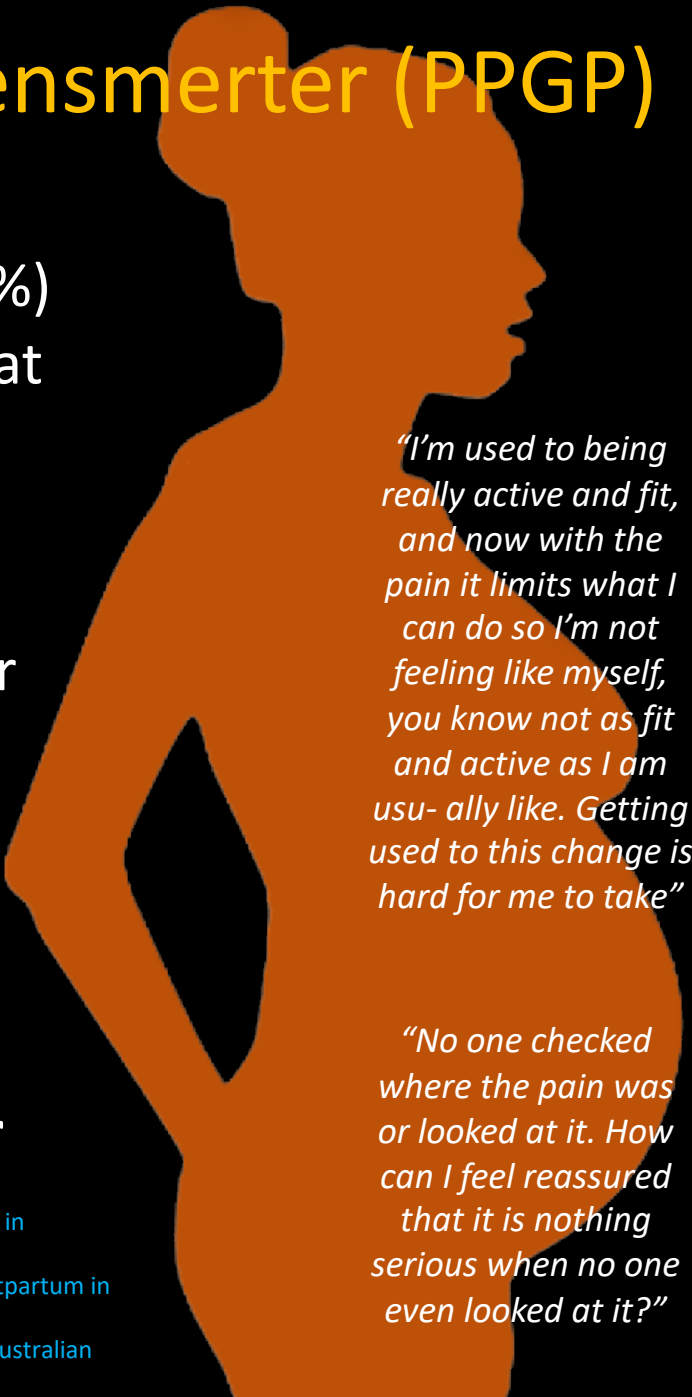
Cohen SP. Epidemics, evolution, and sacroiliac joint pain. *Reg Anesth Pain Med.* 32(1): 3-6, 2007

Dagens Målsetning:

- Prøve å stille klokken frem til 12.02 gjennom
 - Diskutere den betydningen leddet kan ha for smerte
 - Å ha fokus på strukturer relevant for nocisepsjon
 - Bygge ett narrativ for både kliniker og pasient

Svangerskapsrelaterte Bekkensmerter (PPGP)

- **Epidemiologi:**
 - Estimert til å ligge rundt 50 % (<89.9%)
 - Selvbegrensende, men tall indikerer at 33% av kvinner fortsatt har plager 12 uker etter fødsel; 25% ett år etter
- **Etiologi:**
 - Fortsatt uavklart og mange hypoteser
 - Mange potensielle smertekilder
- **Faktorer som påvirker prognose**
 - Smerteintensitet
 - Smerter både SIL og symfyse
 - Sammensatte MSK plager
 - **Opplevelse av å ikke bli tatt på alvor**

A large, dark blue silhouette of a pregnant woman is positioned on the right side of the slide. The silhouette is facing right, with her head slightly turned towards the viewer. The shape of the silhouette clearly shows the pregnant belly.

"I'm used to being really active and fit, and now with the pain it limits what I can do so I'm not feeling like myself, you know not as fit and active as I am usually like. Getting used to this change is hard for me to take"

"No one checked where the pain was or looked at it. How can I feel reassured that it is nothing serious when no one even looked at it?"

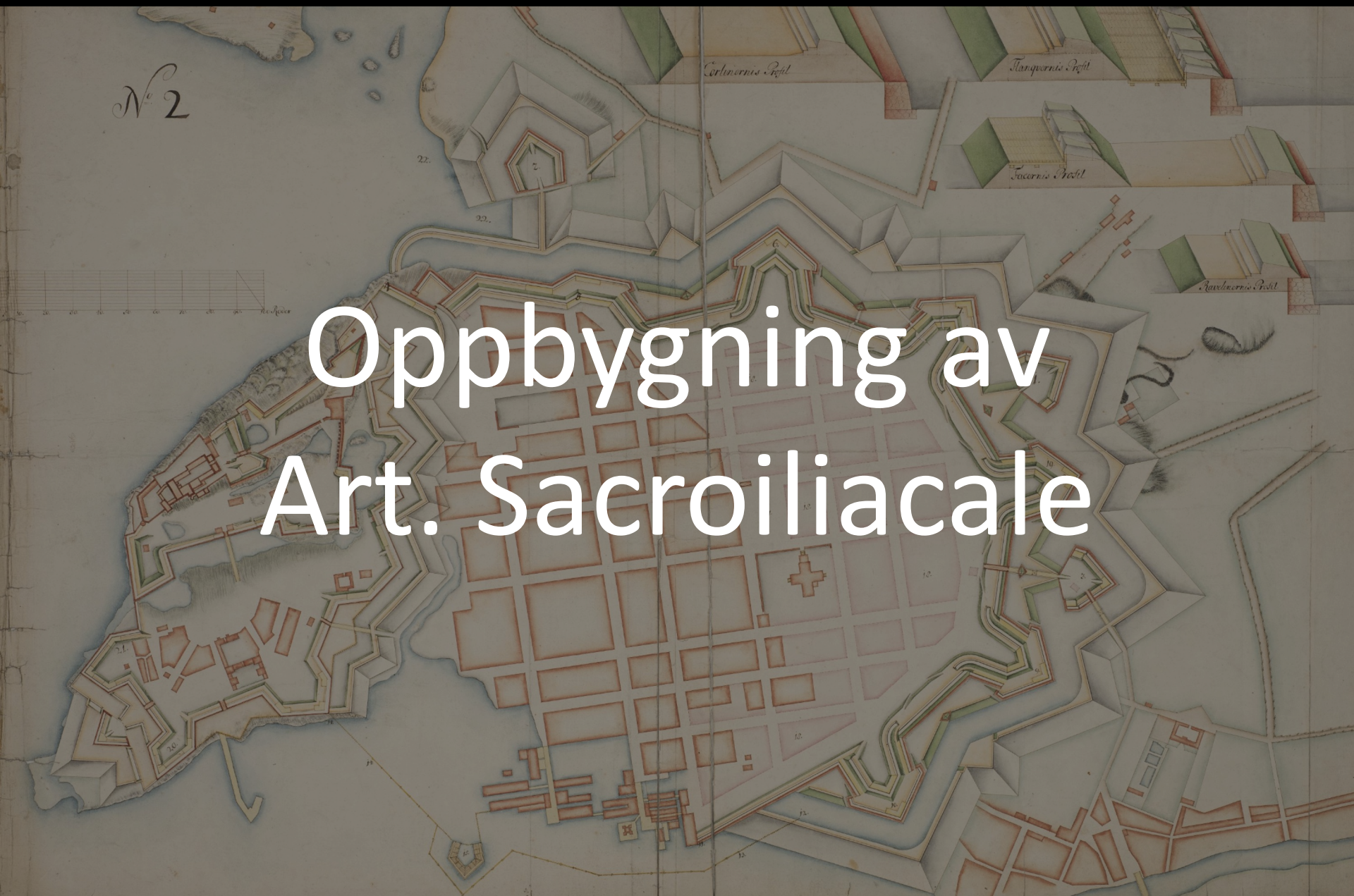Gutke A, Boissonault J, Brook G, Stuge B. The severity and impact of of pelvic girdle pain and low-back pain in pregnancy: a multinational study. *Journal of Women's Health* 27(4): 510-517, 2018

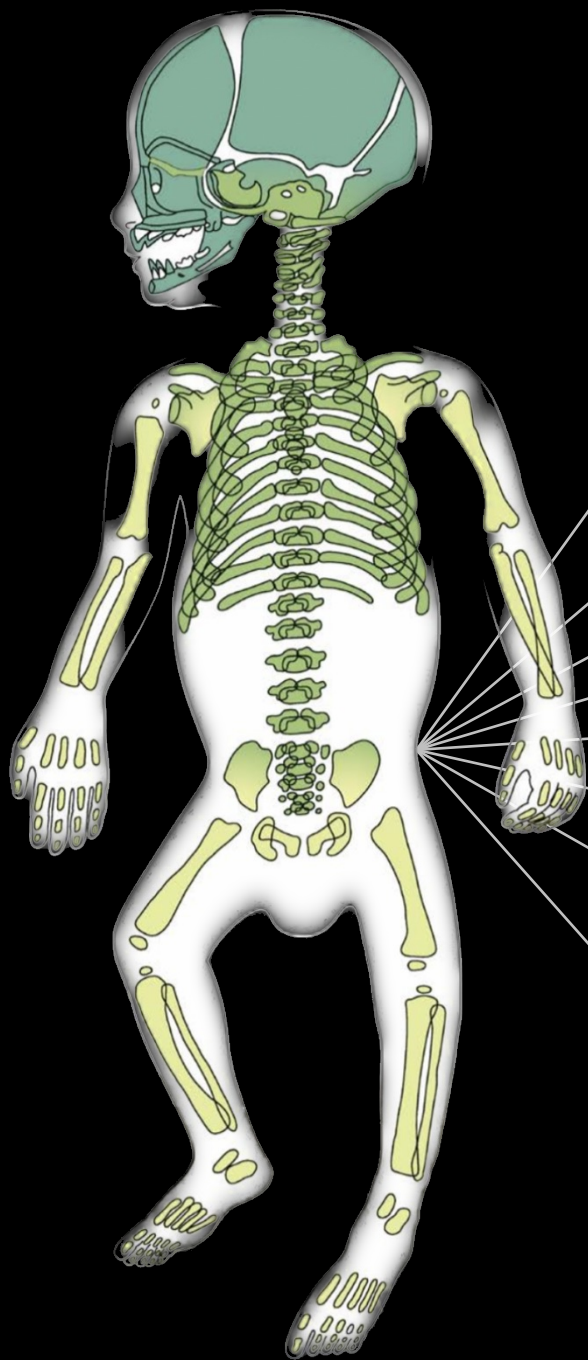
Gunn D et al. Trajectories of upper back, lower back, and pelvic girdle pain during pregnancy and early postpartum in primiparous women. *Women's Health* Vol. 15: 1 – 8, 2019

Cepnija D et al. "This is hard to cope with": the lived experience and coping strategies adopted amongst Australian women with pelvic girdle pain in pregnancy. *BMC pregnancy and Childbirth* (2022): 22: 96

N^o 2

Oppbygning av Art. Sacroiliacale





7 Svangerskapsuke:

Ilium er på plass bak de sakrale virvlene som ossifiserer

8 Svangerskapsuke:

Utviklingen av SI – leddet begynner

10 Svangerskapsuke:

SI – leddene begynner danne sine leddhuler

13 Svangerskapsuke:

Ilium ossifiserer og leddflatene dekkes med brusk

18 Svangerskapsuke:

Lig. Sacrospinale dannes som ett løst band

7 Svangerskapsmåned:

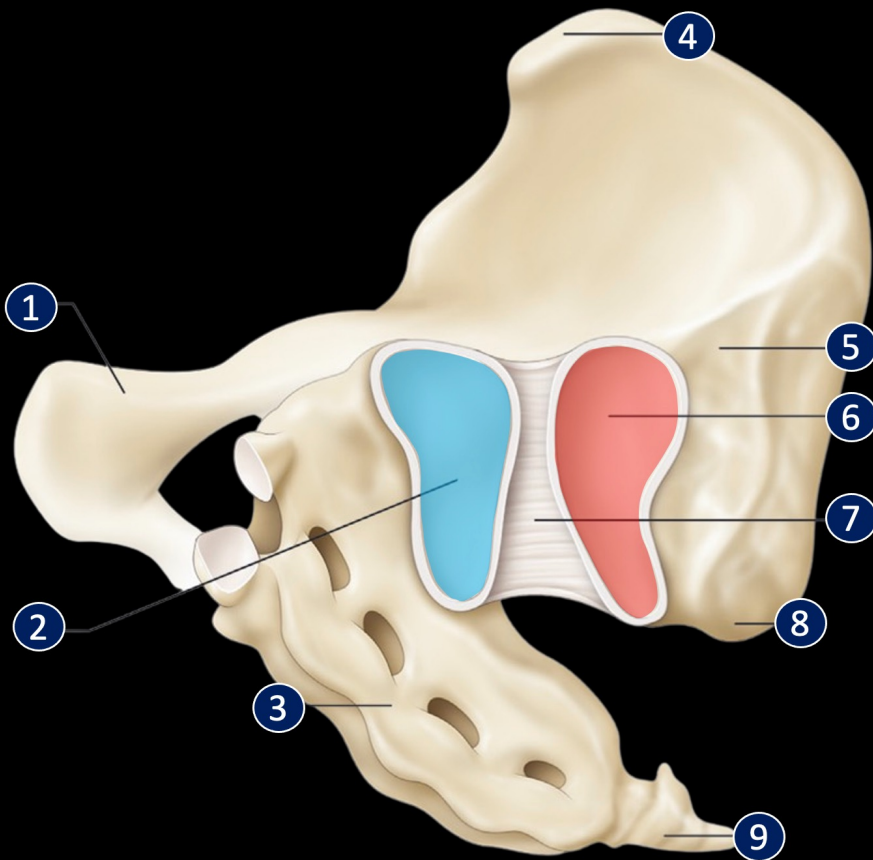
SI – leddet har utviklet signifikant mobilitet og Lig. Sacrotuberale er velutviklet

8. Svangerskapsmåned:

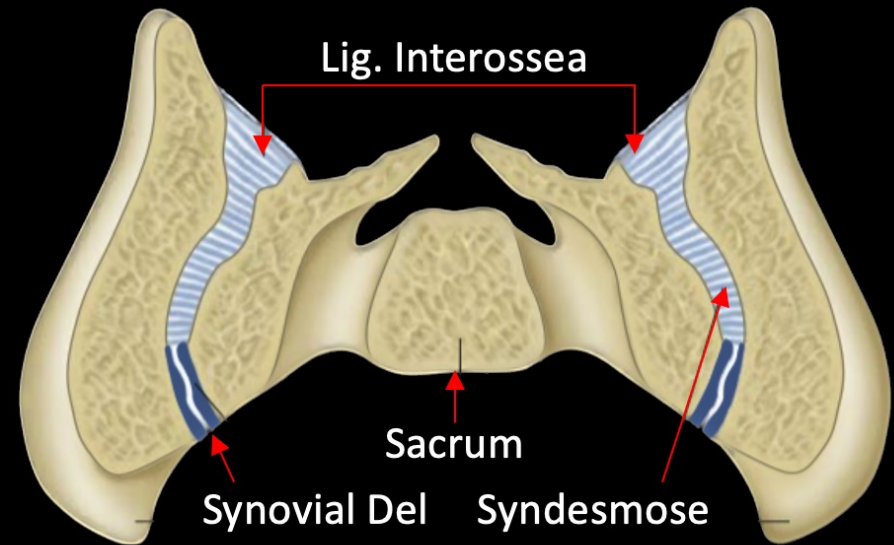
SI leddhulen er fullstendig utviklet. Og det samme med Lig. Sacrospinale

Etter fødsel:

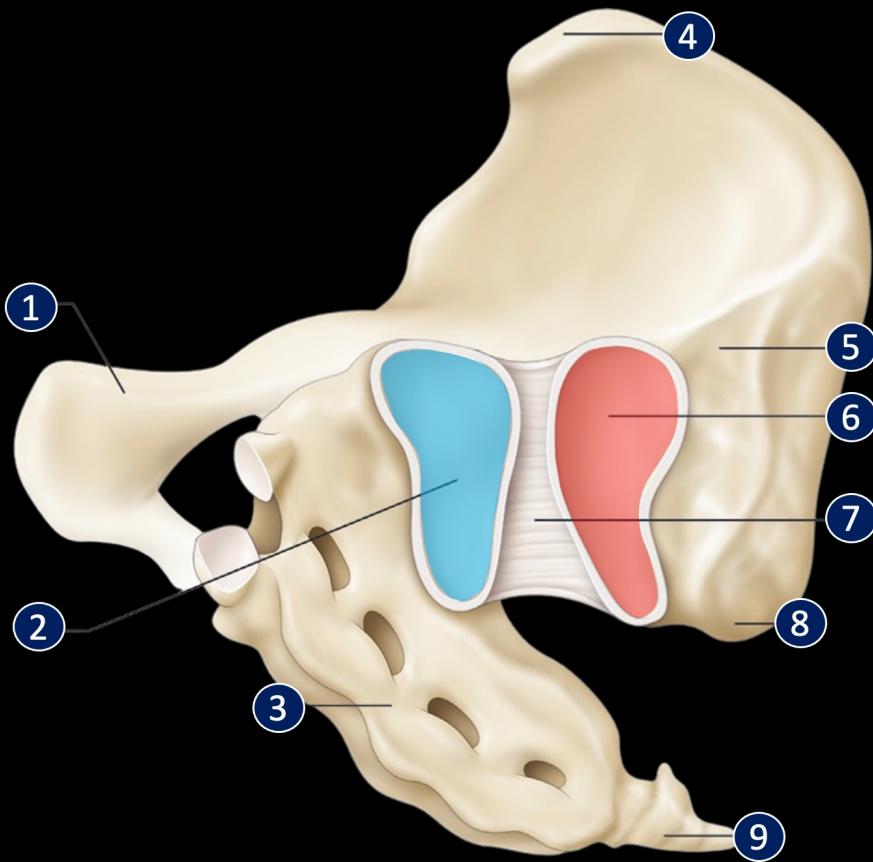
Leddets synovia utvikles og kan nå visualiseres



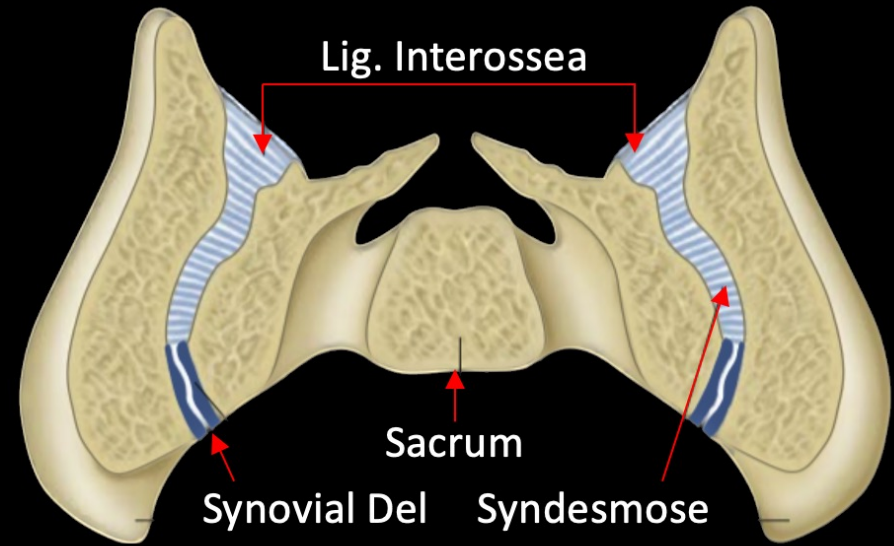
1. Os Pubis
2. SI Ledge/Plate Os Sacrum
3. Sacrum
4. SIAS
5. Tuberositas Iliacale
6. SI Ledge/Plate Os Ilium
7. Lig. Sacroiliacale Anterior
8. SIPS
9. Os Coccyx



Study	Joint type classification	Assessment made from	Technique
von Luschka, 1854 (25)	diarthrodial	structural features	histology and dissection
Albee, 1909 (50)	diarthrodial	structural features	cadaveric dissection
Dieulafoy and Saint-Martin, 1912 (53)	condylarthrosis ^a	shape and movement	cadaveric dissection
Brooke, 1923 (30)	diarthrodial	degree of movement	cadaveric dissection
Sashin, 1930 (55)	diarthrodial	structural features	cadaveric dissection
Hakim, 1937 (57)	diarthro-amphiarthrosis	structural features	histology and dissection
Delmas, 1950 (52)	diarthro-amphiarthrosis	structural features	N/A
Macdonald and Hunt, 1952 (32)	diarthrodial	structural features	histology and dissection
Bowen and Cassidy, 1981 (51)	diarthrodial	structure and movement	histology and dissection
Gerlach and Lierse, 1992 (42)	amphiarthrosis	N/A*	dissection and imaging
Puhakka et al., 2004 (54)	diarthro-amphiarthrosis	structural features	histology
Egund and Jurik, 2014 (141)	diarthro-amphiarthrosis	structural features	histology



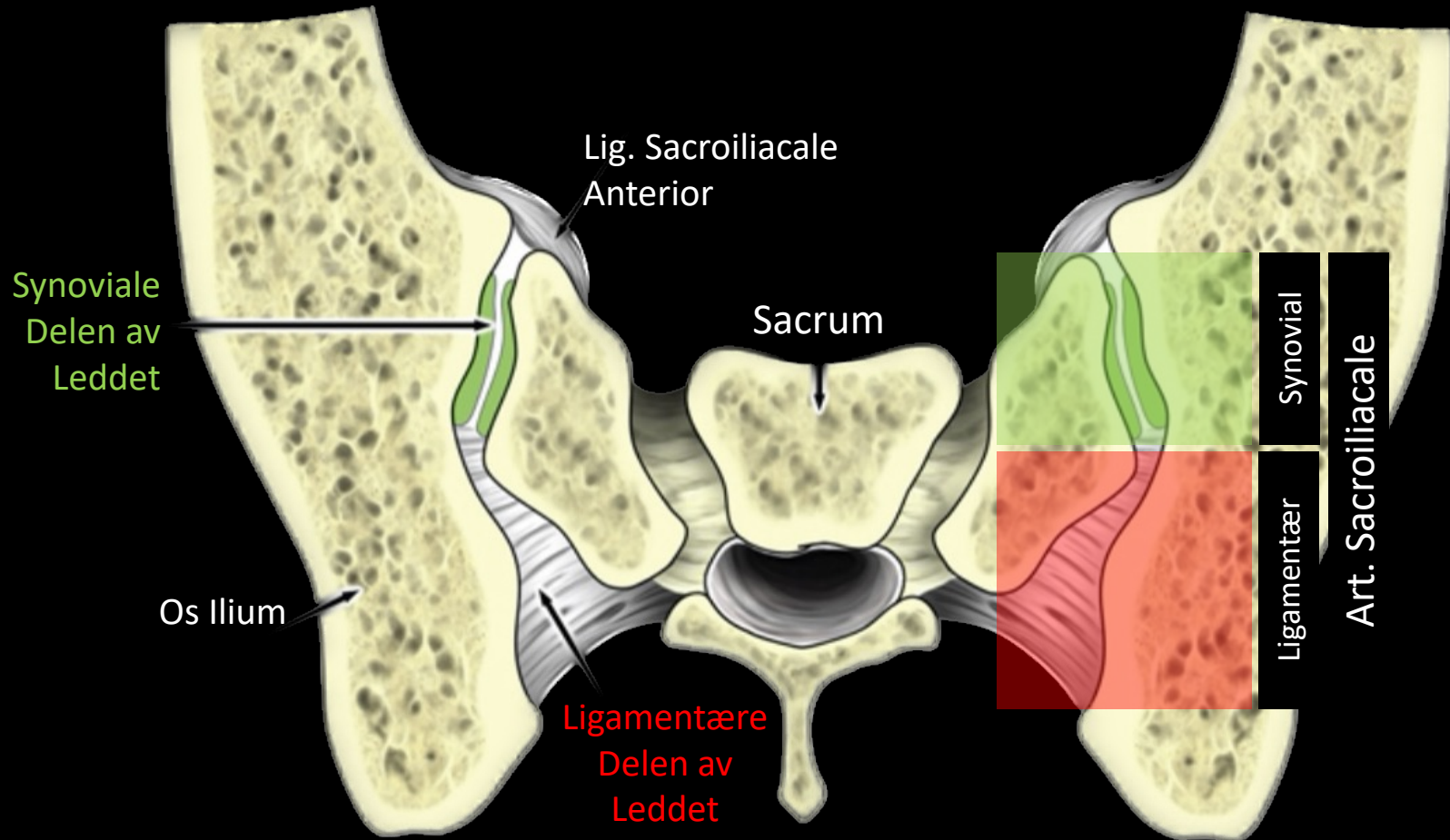
1. Os Pubis
2. SI Ledgeplate Os Sacrum
3. Sacrum
4. SIAS
5. Tuberositas Iliakale
6. SI Ledgeplate Os Ilium
7. Lig. Sacroiliacale Anterior
8. SIPS
9. Os Coccyx



	Joint type classification	Assessment made from	Technique
von Lub	diarthrodial	structural features	histology and dissection
Albes	diarthrodial	structural features	cadaveric dissection
Dieulafoy and	condylarthrosis	shape and movement	cadaveric dissection
	diarthrodial	degree of movement	cadaveric dissection
	diarthrodial	structural features	cadaveric dissection
	diarthro-amphiarthrosis	structural features	cadaveric dissection
	diarthro-amphiarthrosis	structural features	N/A
Mac	diarthrodial	structural features	histology and dissection
Bow	diarthrodial	structure and movement	histology and dissection
Gerla	amphiarthrosis	structure and movement	dissection and imaging
Pu	diarthro-amphiarthrosis	structural features	histology
Egu	diarthro-amphiarthrosis	structural features	histology

Hvordan klassifiserer vi leddet?

Ett Ledd med To Kompartment

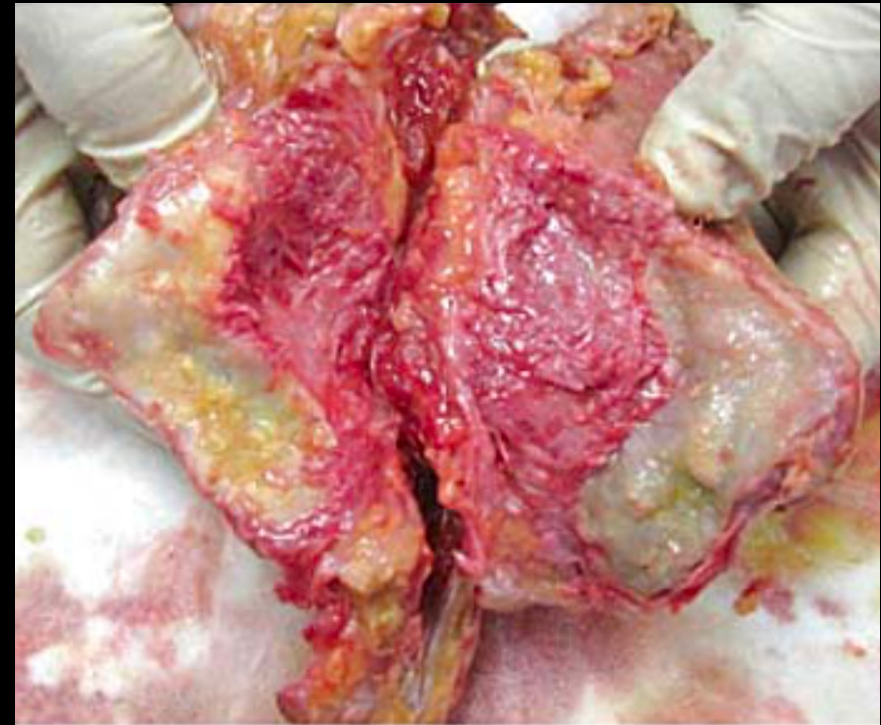
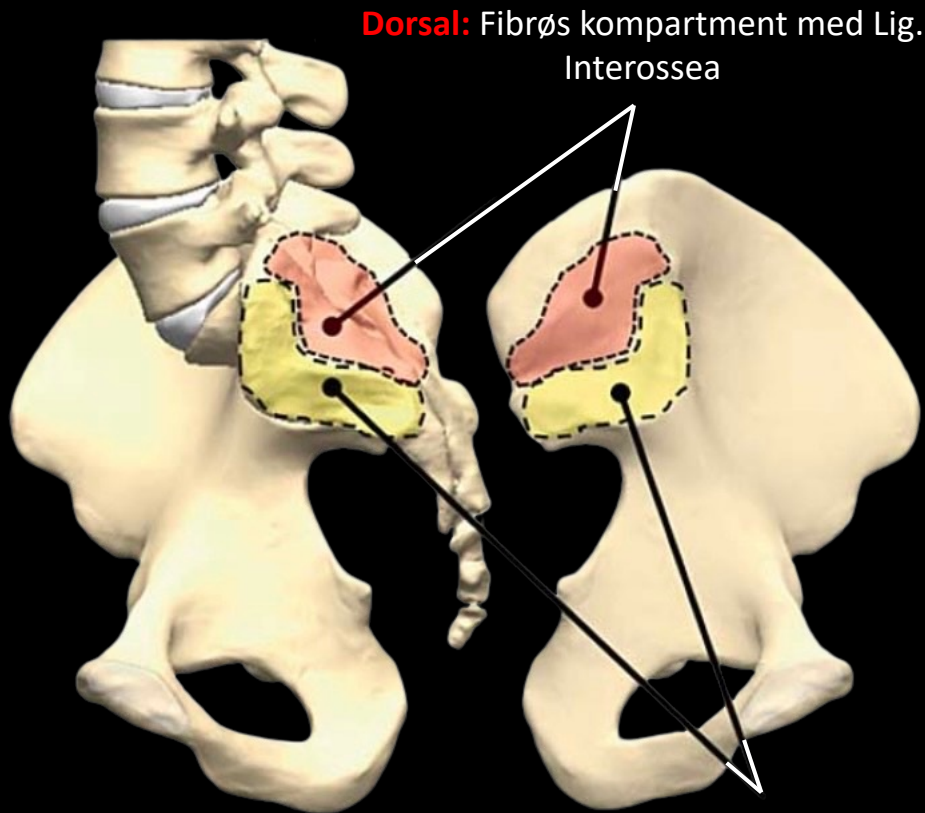


Artikulær Kompartiment: synoviale delen av leddet

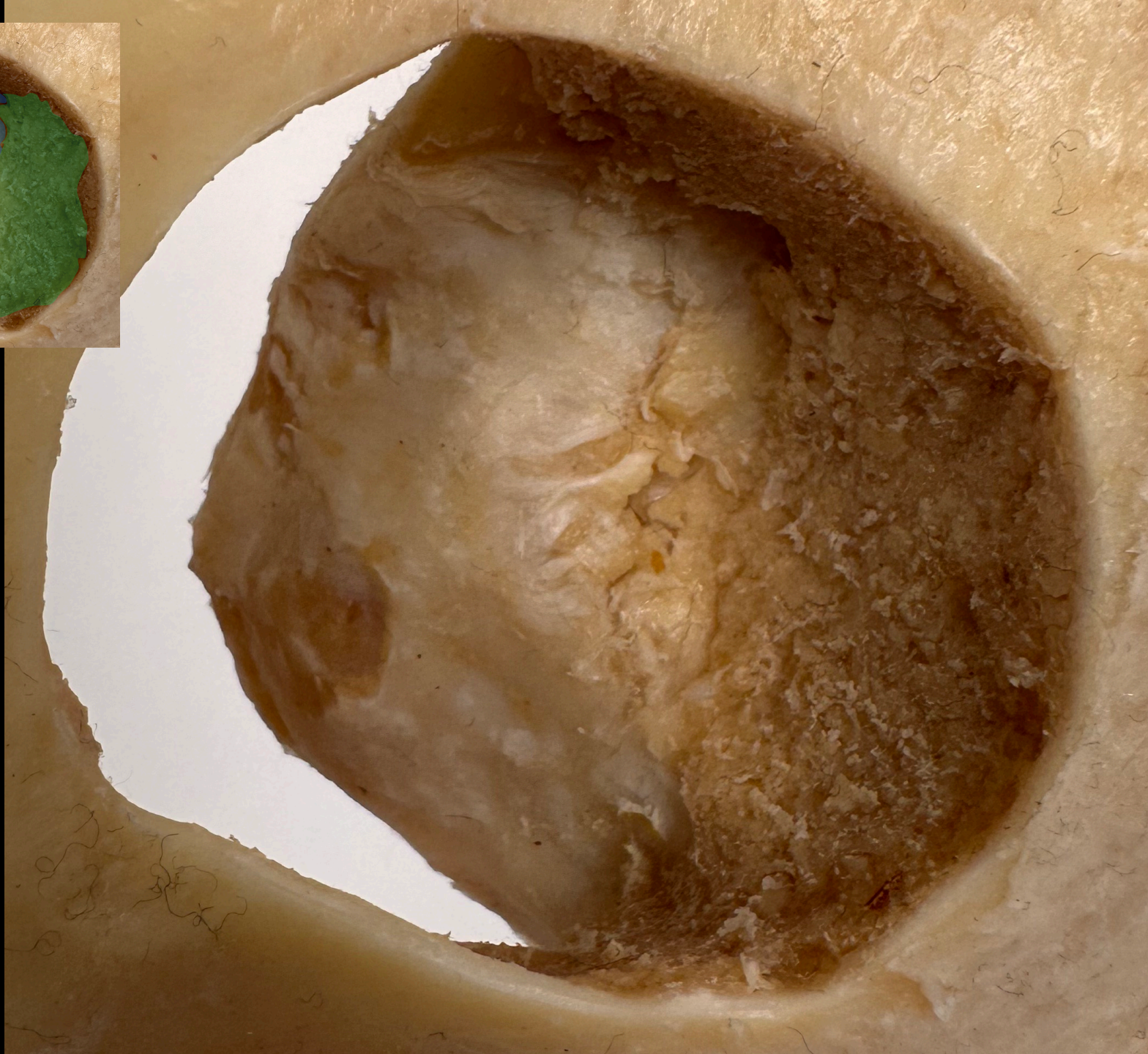
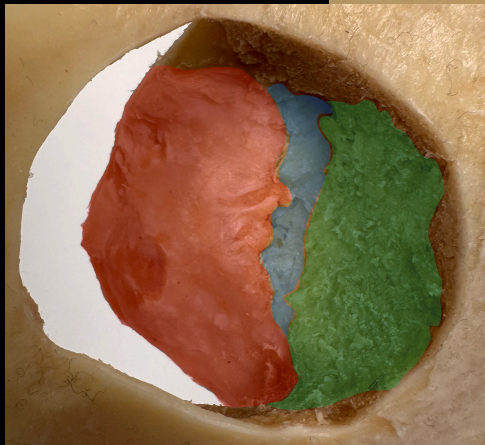


Ligamentær Kompartiment: Lig. Interossea og Sacroiliacale Post.

Det Sacroiliacale Leddkomplekset

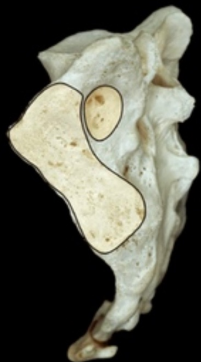
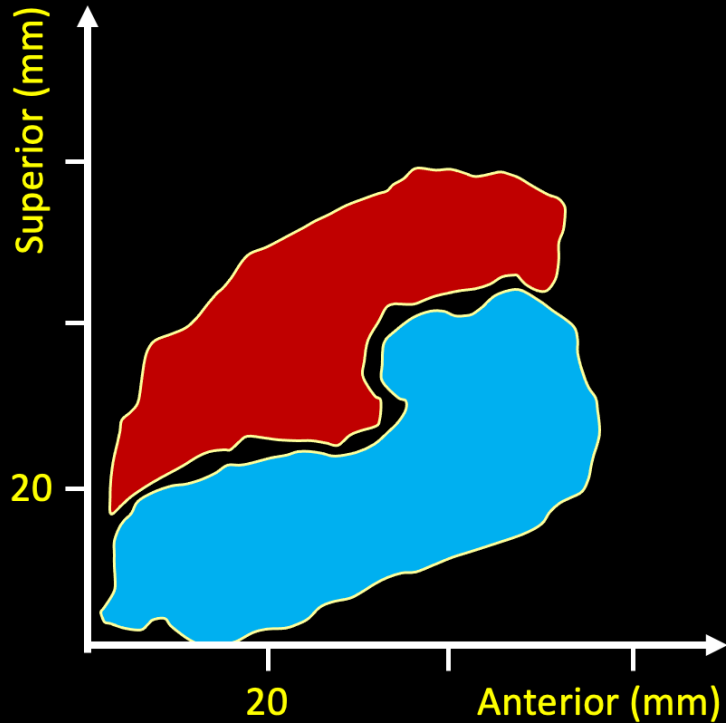


Ventral: Artikulær kompartiment med den kartilaginøse delen av leddet

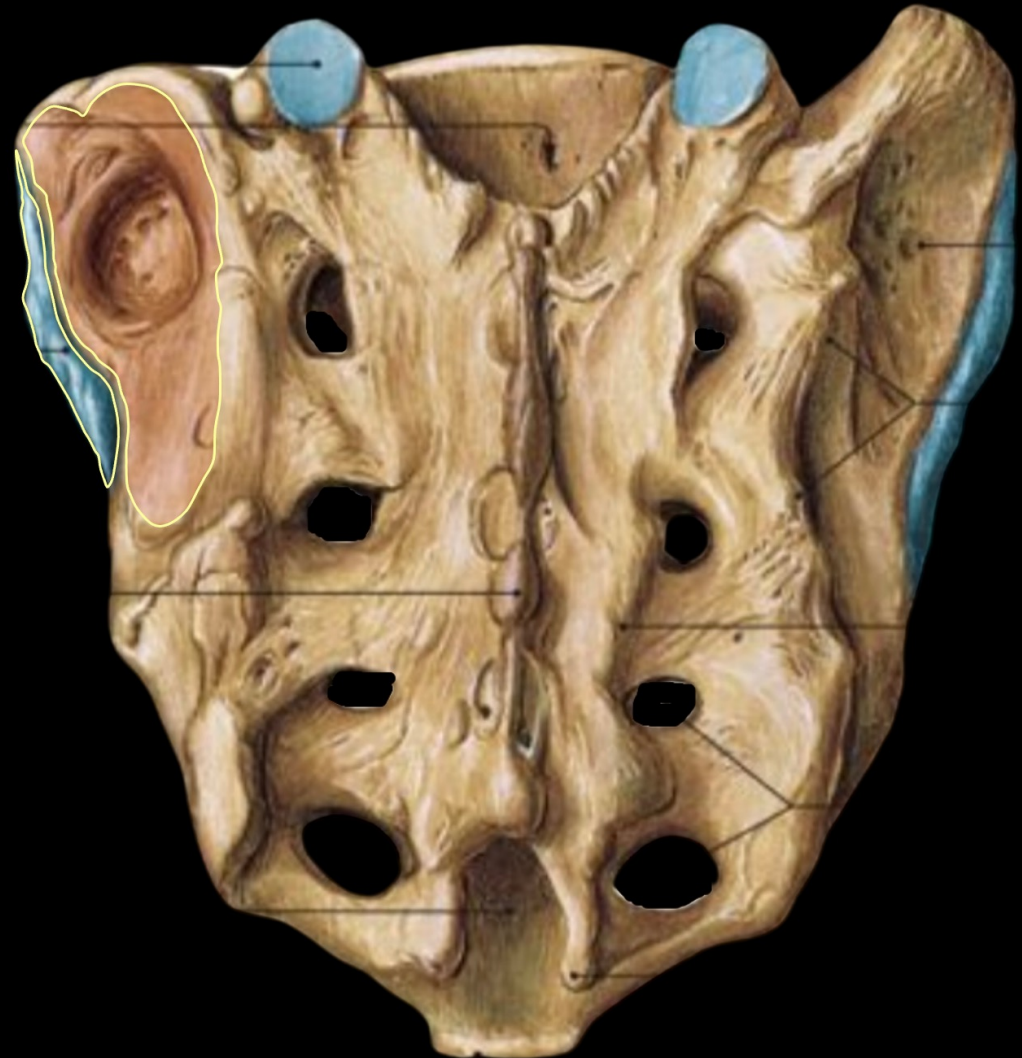


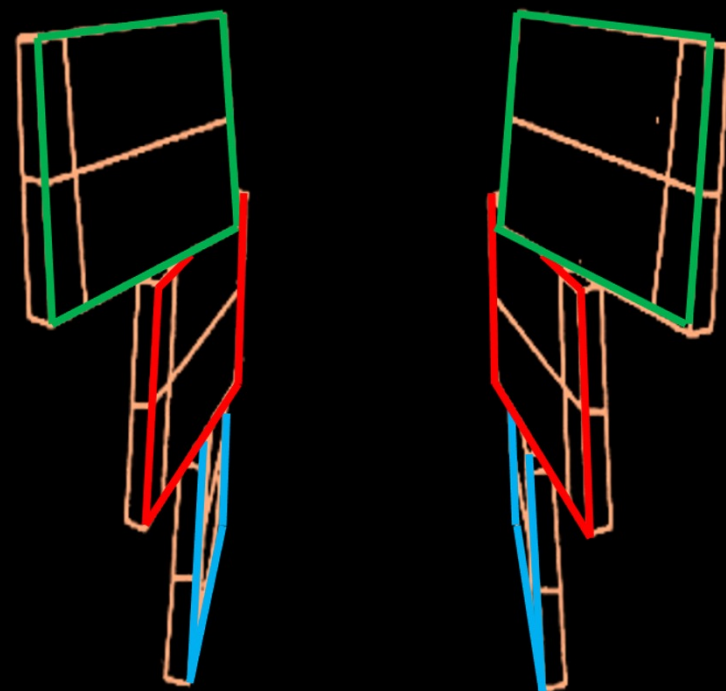
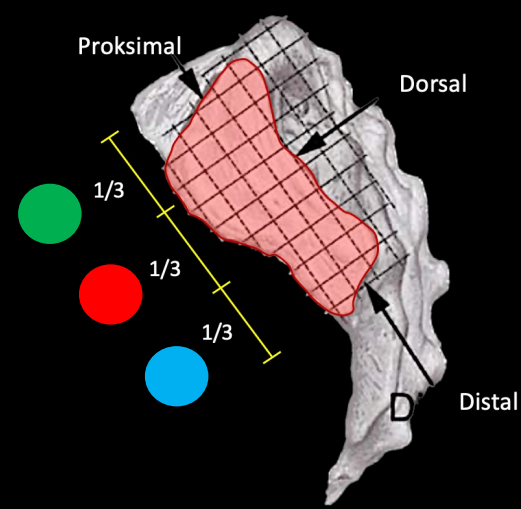
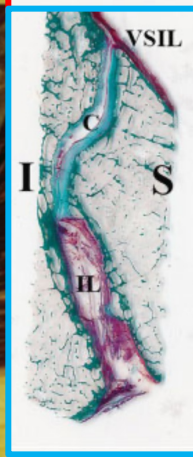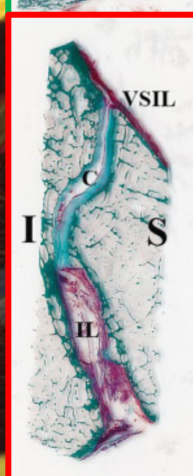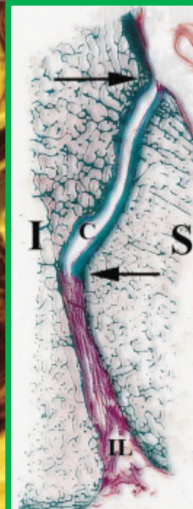
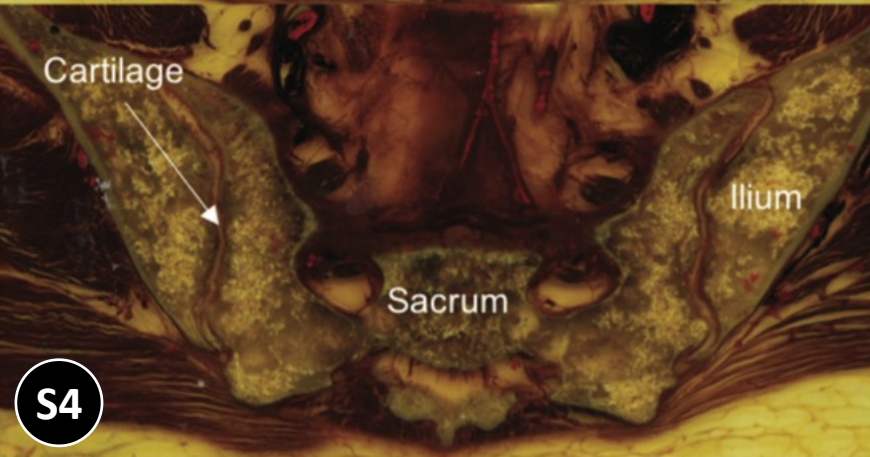
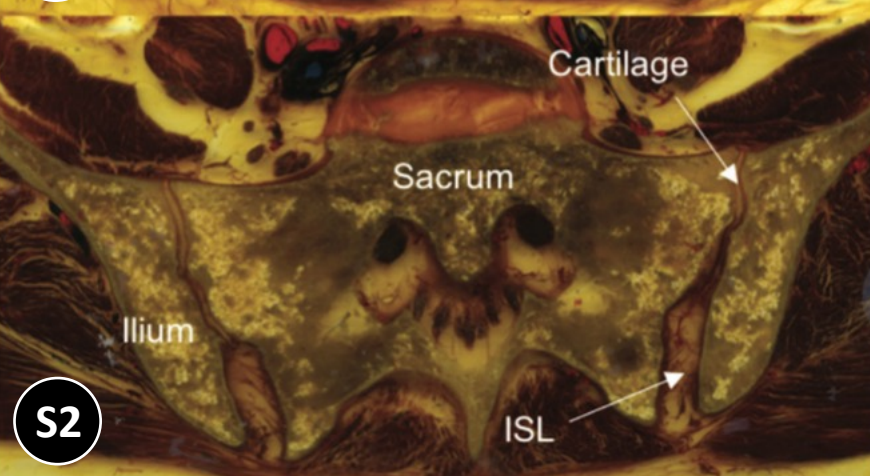
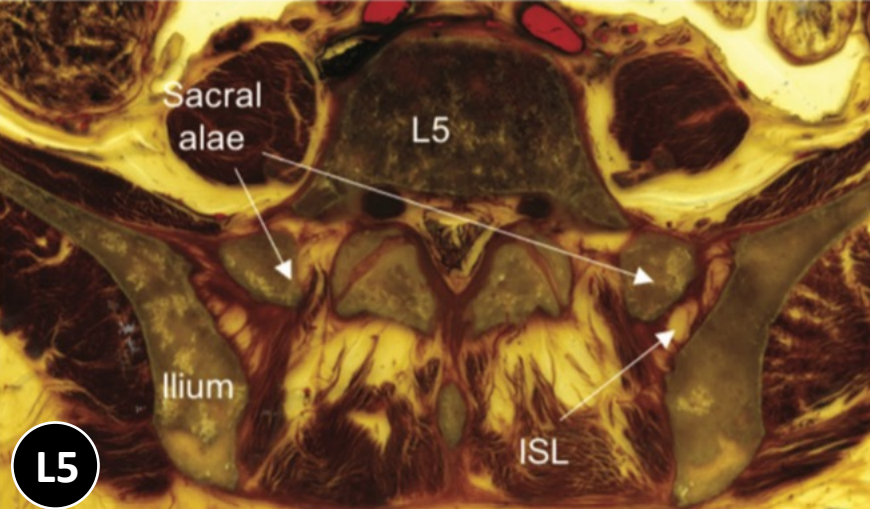
Anatomisk Lab
School of Health Sciences

Sacroiliac, Aksiale SI og Interossøse Regionene




ILIUM	SACRUM	ILIUM	SACRUM
♂ right	♀ left	♀ left	♂ right
♀ left	♂ right	♂ right	♀ left
♂ right	♀ left	♀ left	♂ right
♀ left	♂ right	♂ right	♀ left
♂ right	♀ left	♀ left	♂ right
♀ left	♂ right	♂ right	♀ left
♂ right	♀ left	♀ left	♂ right
♀ left	♂ right	♂ right	♀ left
♂ right	♀ left	♀ left	♂ right
♀ left	♂ right	♂ right	♀ left





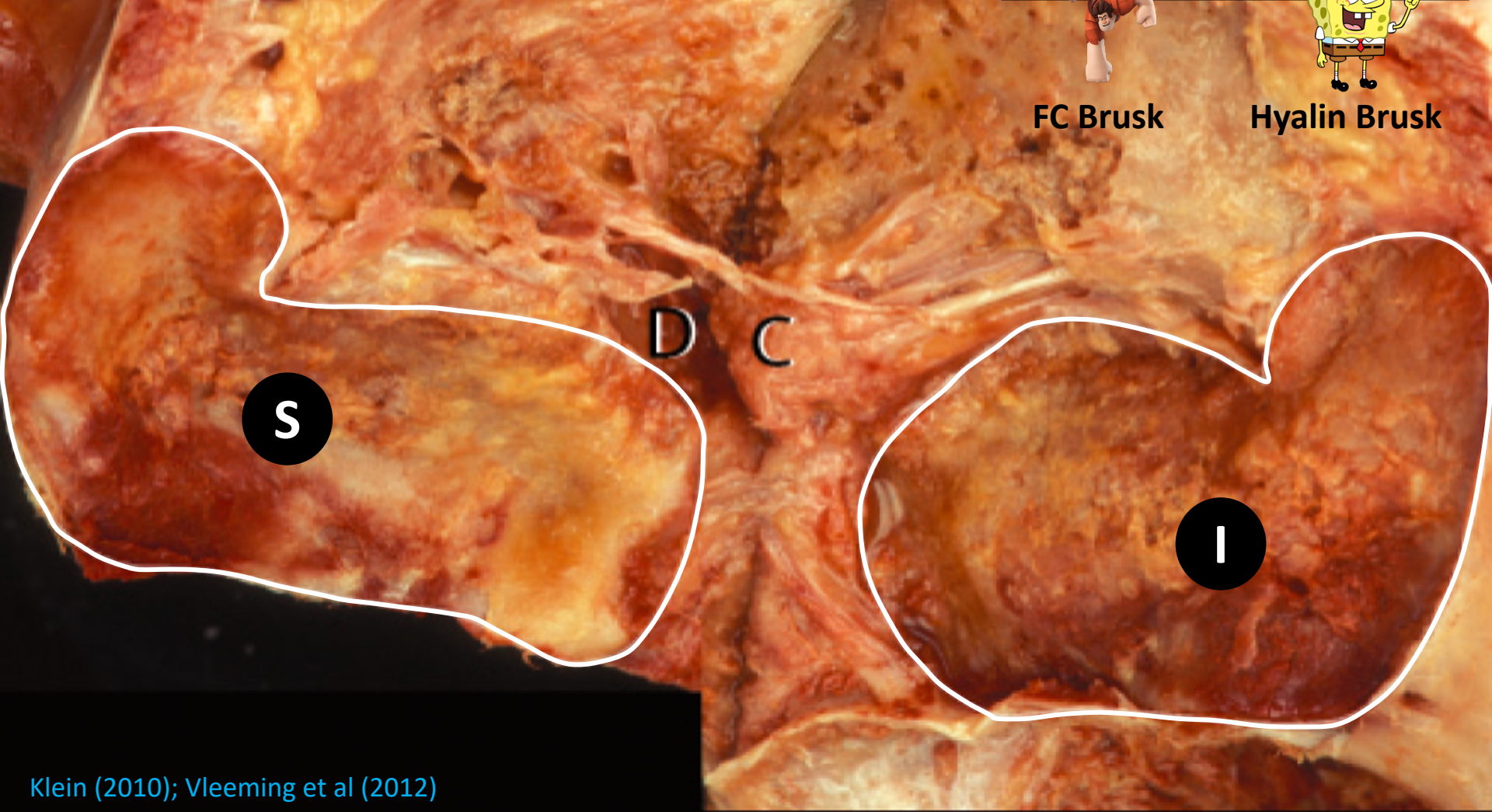
Solonen KA. The sacroiliac joint in the light of anatomical, roentgenological and clinical studies. *Acta Orthop Scand Suppl* 1957; 27:1–127; Puhkka KB et al. MR imaging of the normal sacroiliac joint with correlation to histology. *Skeletal Radiol* (2004) 33: 15; Egund N et al. Anatomy and histology of the sacroiliac joints. *Semin Musculoskel Radiol* 2014; 18: 332-340

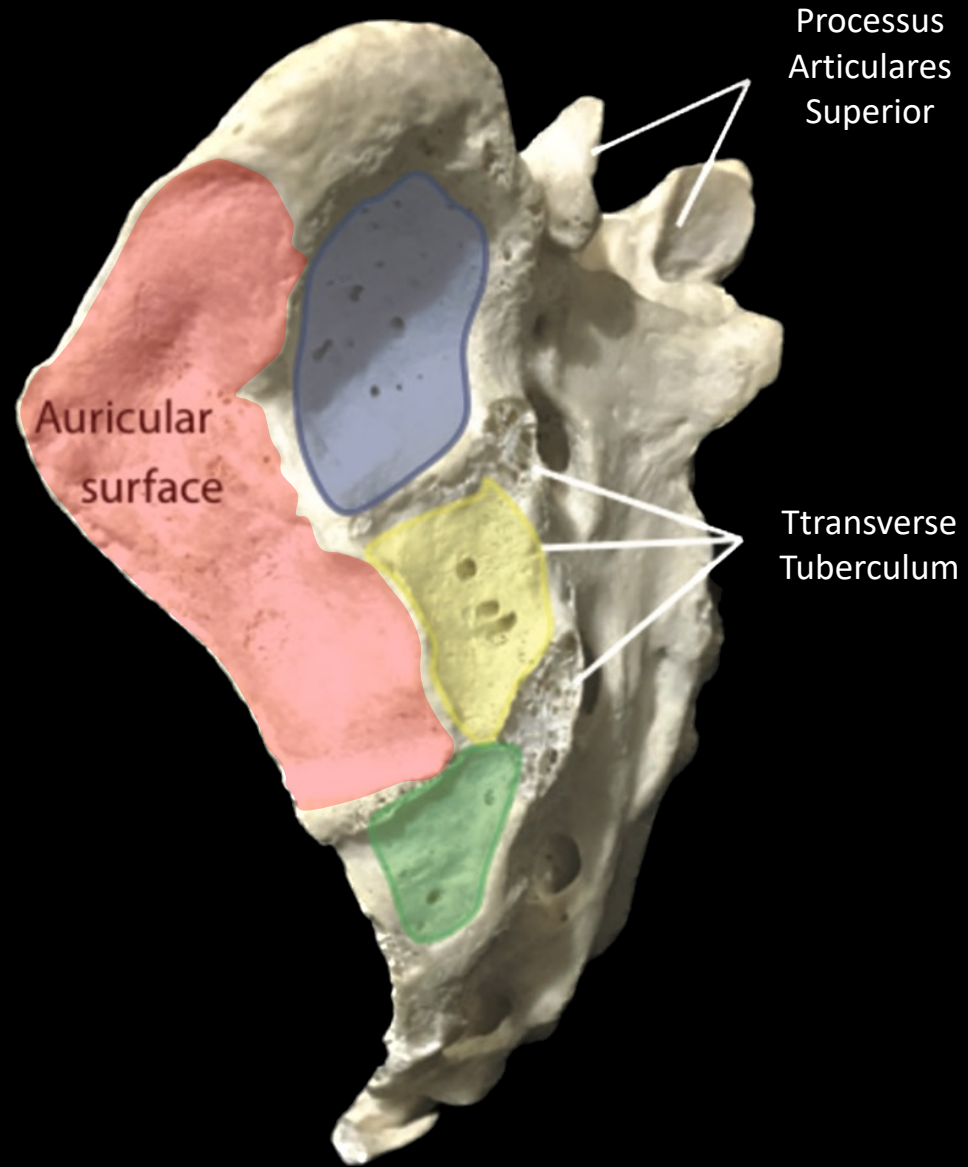
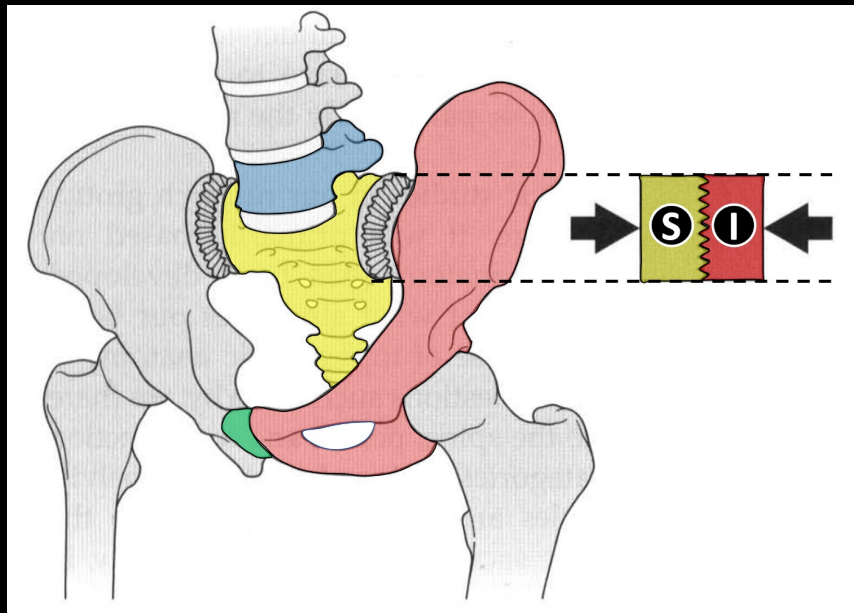
- Iliakal Leddflate: **13.6 cm²**
 - Sacral Leddflate: **14.4 cm²**
 - Kontaktflate: **80%**
- De er *VELDIG* inkongruente



FC Bruskk

Hyalin Bruskk





Kileformet Sacrum



Uregelmessige Leddflater



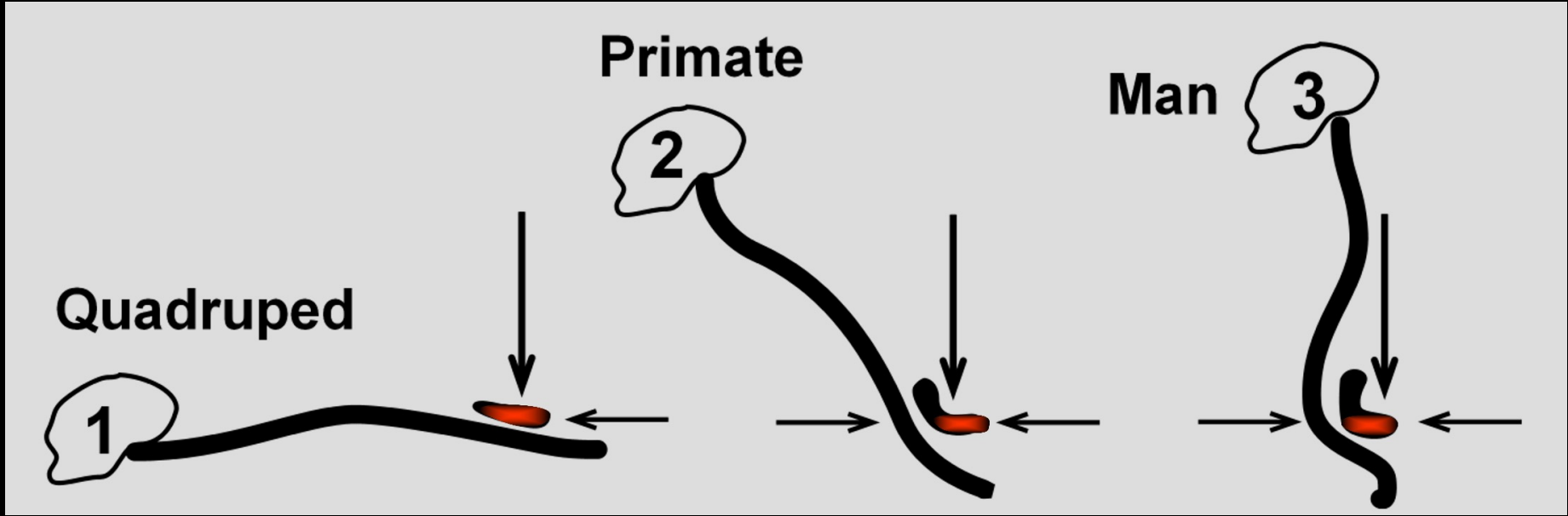
Utallige tuberkler og kanter



Masse Ligamenter



Gode forutsetninger for massiv stabilitet og minimal mobilitet

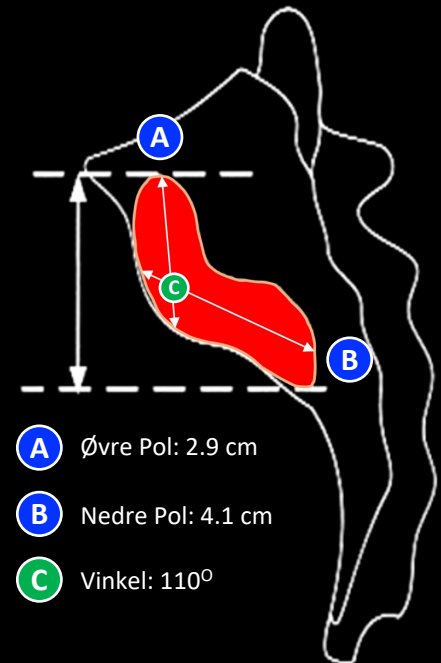
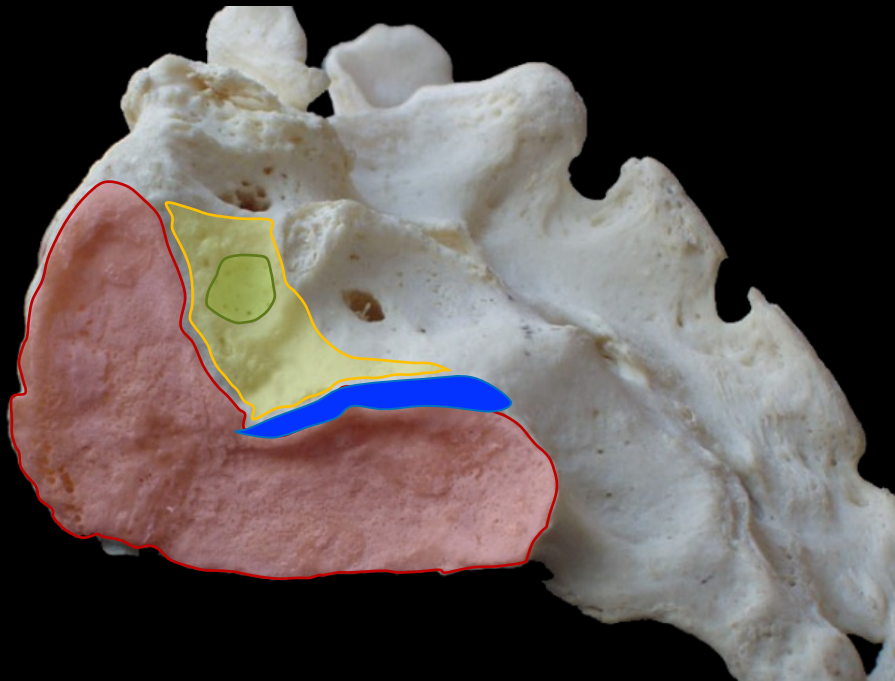


Sacræ
Leddflate

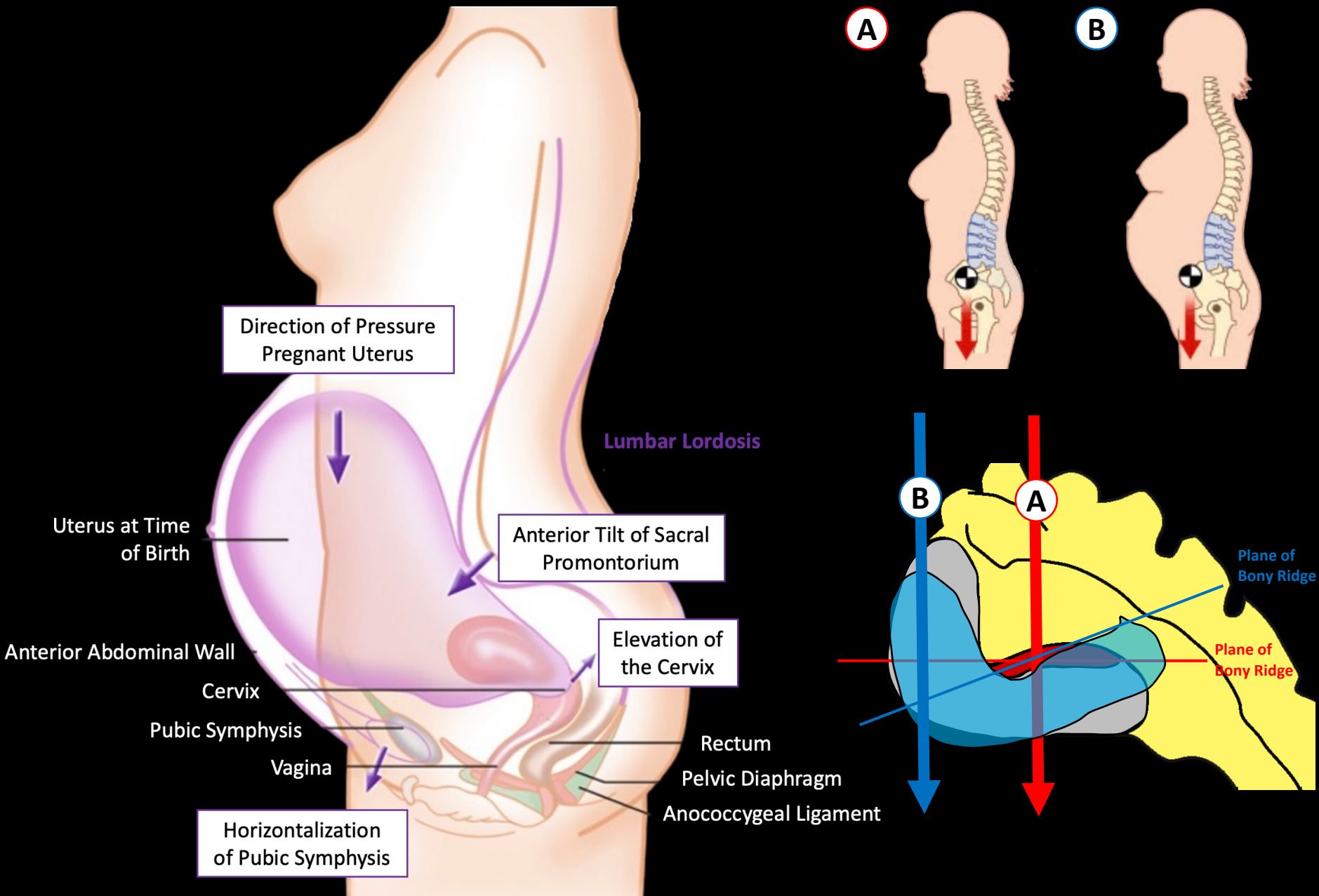
Knokkelkante:
Stabiliserer SIL

Aksiale SI Ledd

Posteriore
Ligamenter

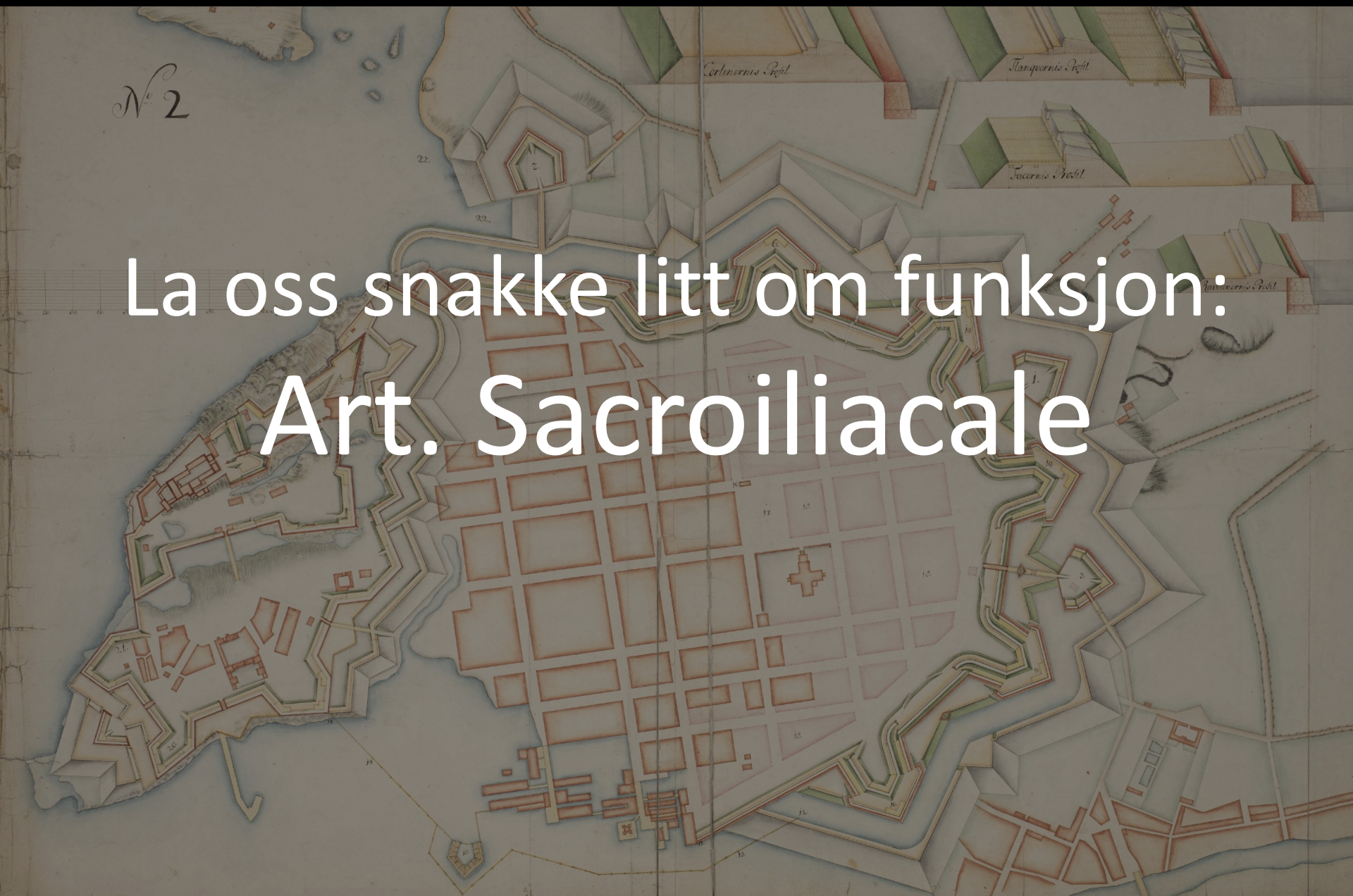

Posturale Endringer under Svangerskap

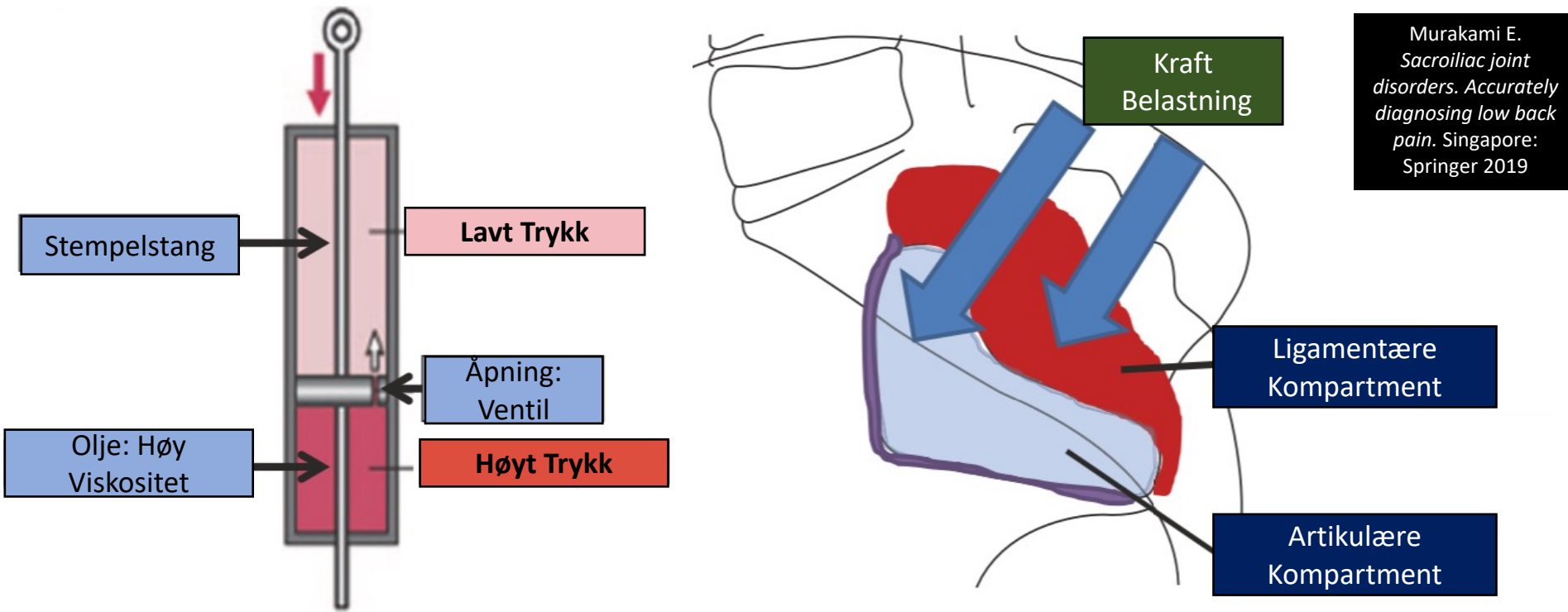


N^o 2

La oss snakke litt om funksjon:
Art. Sacroiliacale

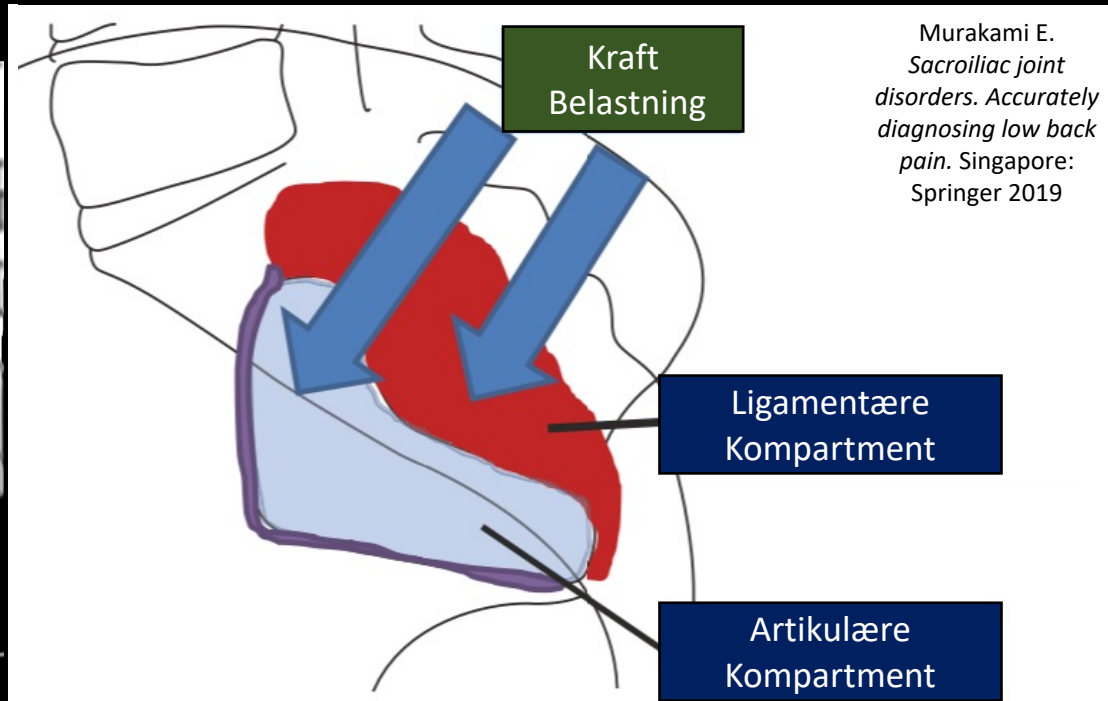
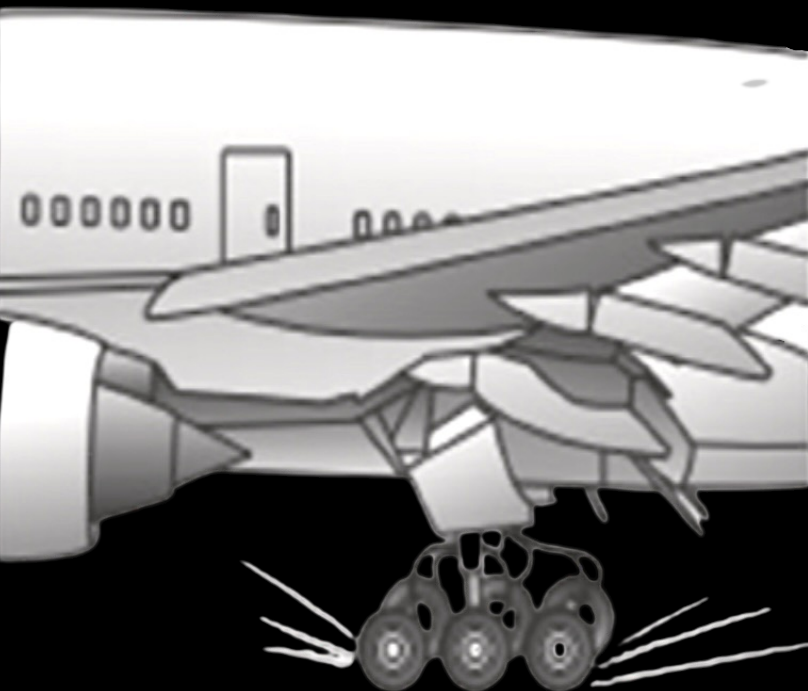


Hvordan kan vi best forstå funksjonen til SI – Leddet?



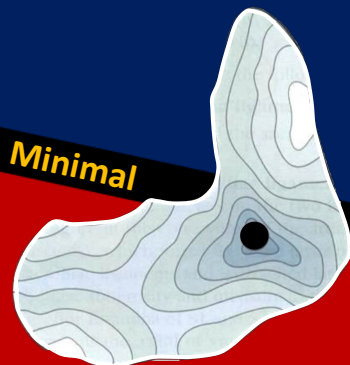- A. Med sine viskoelastiske kvaliteter kan det sammenlignes med en støtdemper: kraftoverføring og kraftabsorpsjon
- B. Som støtdemper skal det redusere effekten av nedadstigende og oppadstigende krefter på bekkenringen
- C. Energiomformer for bevegelsesenergi

Hvordan best beskrive funksjonen til SI – Leddet?



Muskler og fascier:
Aktiv og Passiv Tensjon

Force Closure

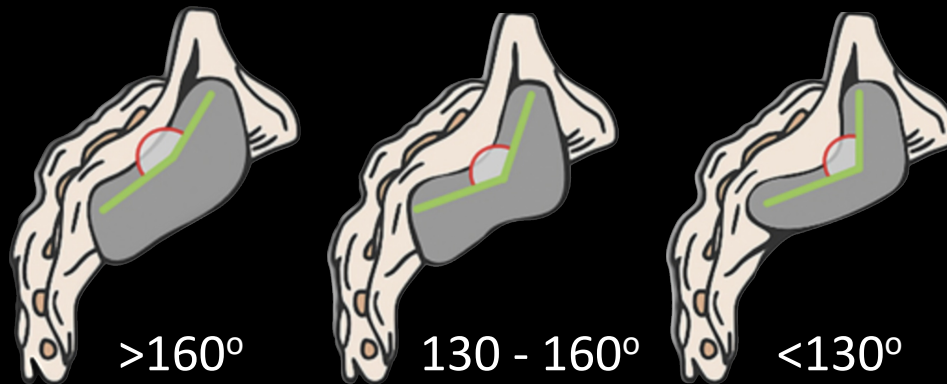


Minimal

Mobilitet

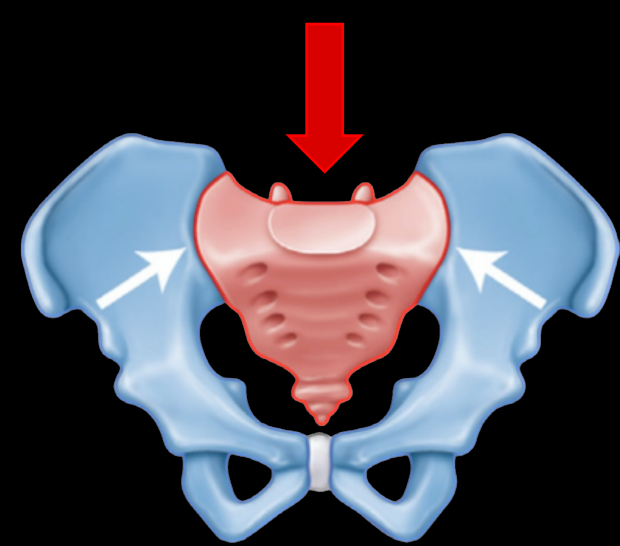
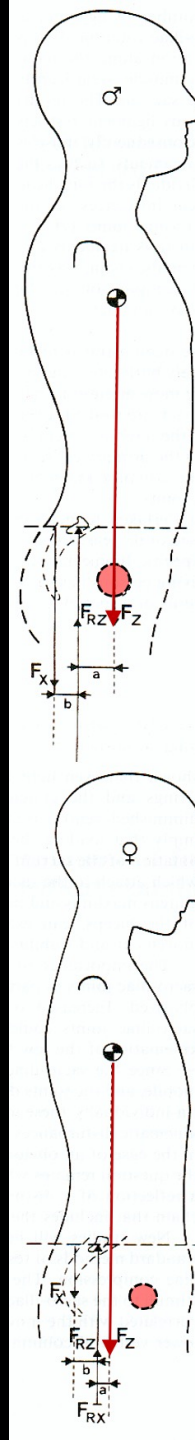
Form Closure

Knokler, ledd og
ligamenter



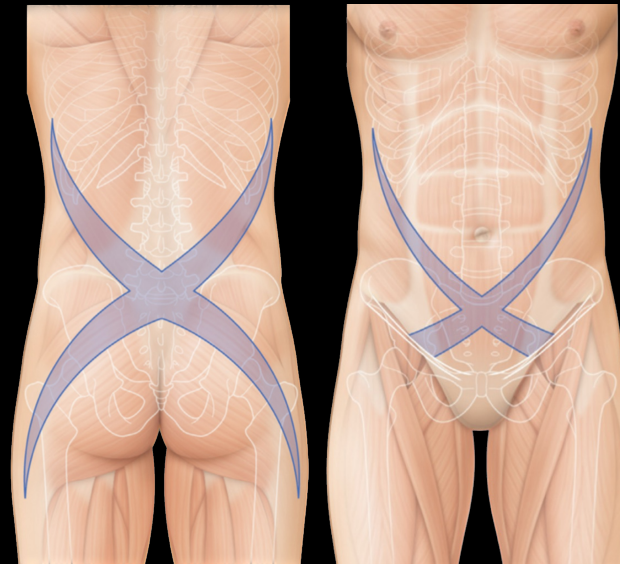
Form Closure

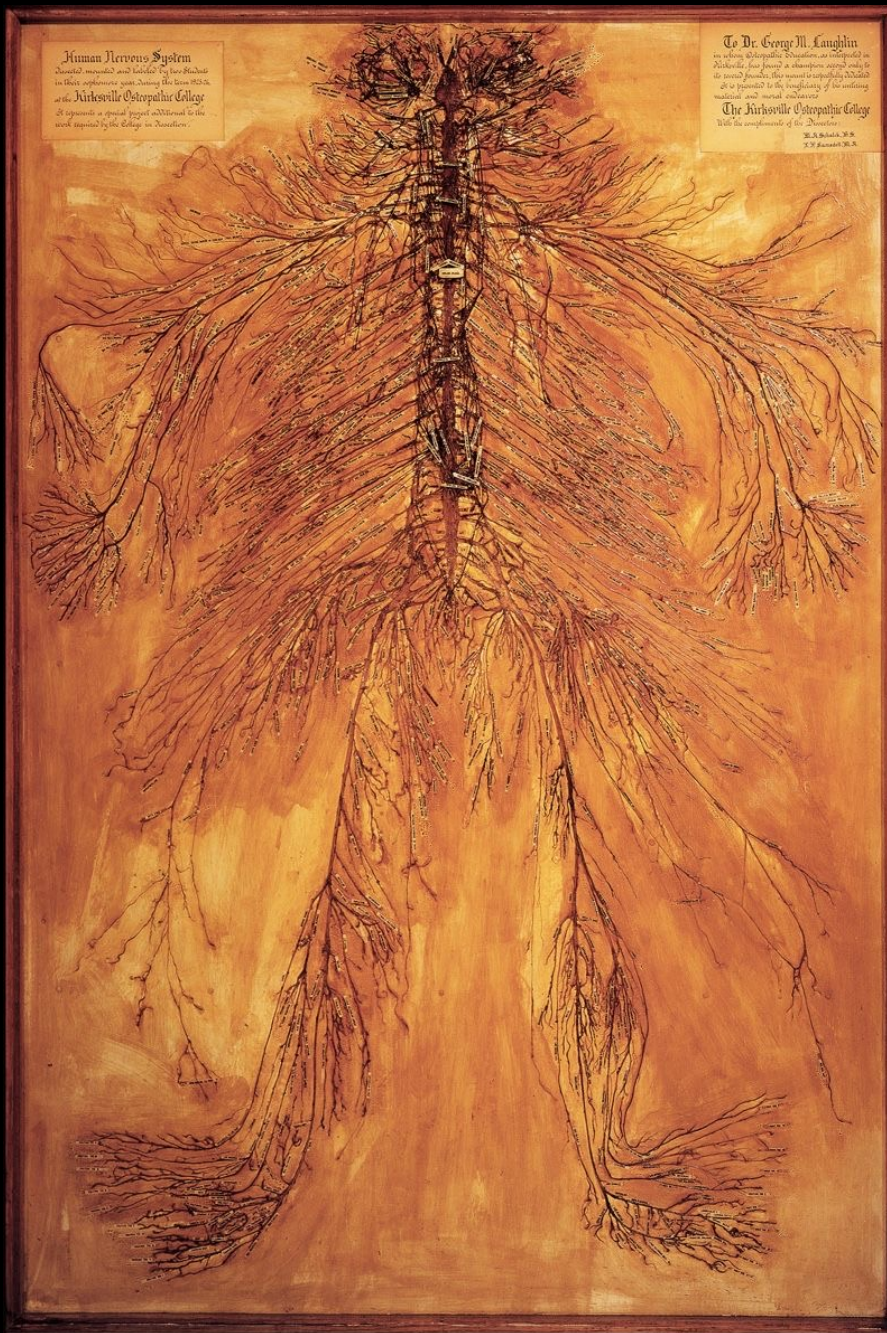
Force Closure



Form på knokler og tensil styrke ligamenter

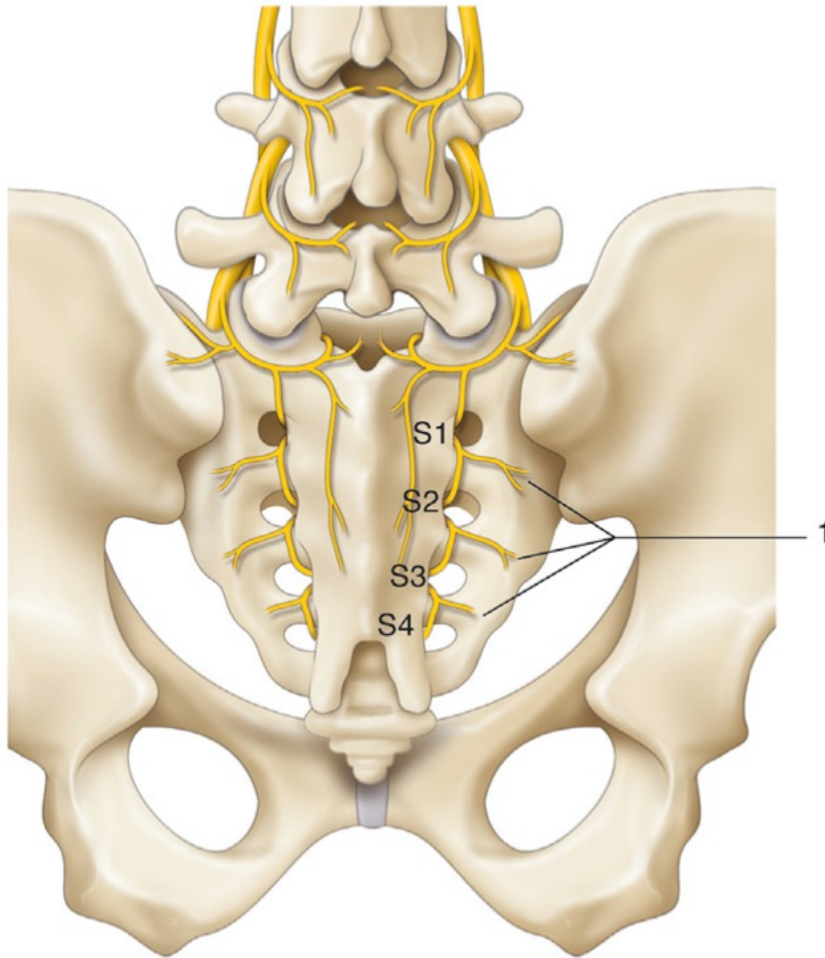
Muskulatur, Fascier og IAP





Nevroanatomy 101

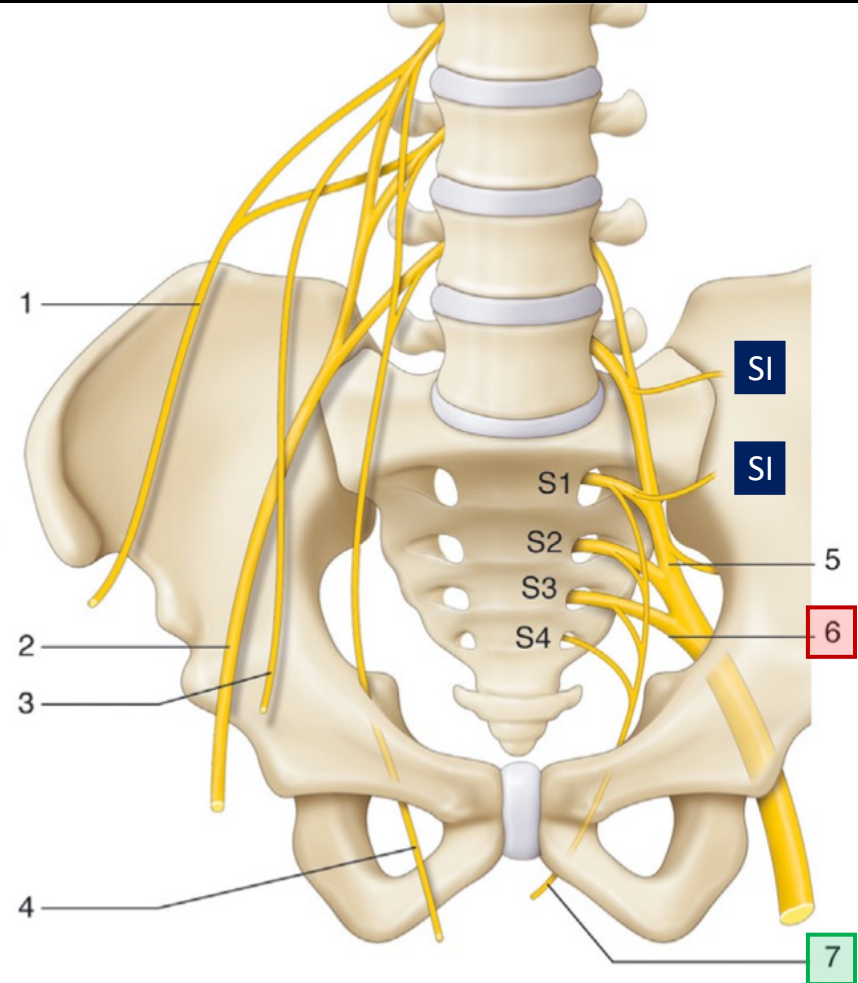
Nervale Strukturer av Interesse



PBSN 1 – 4:

Posterior grener Nn. Sacrales 1 - 4

Viktig for innervasjon av SI – leddet og leddnære ligamenter



SI: Innervasjon Anteriore SI - Leddet

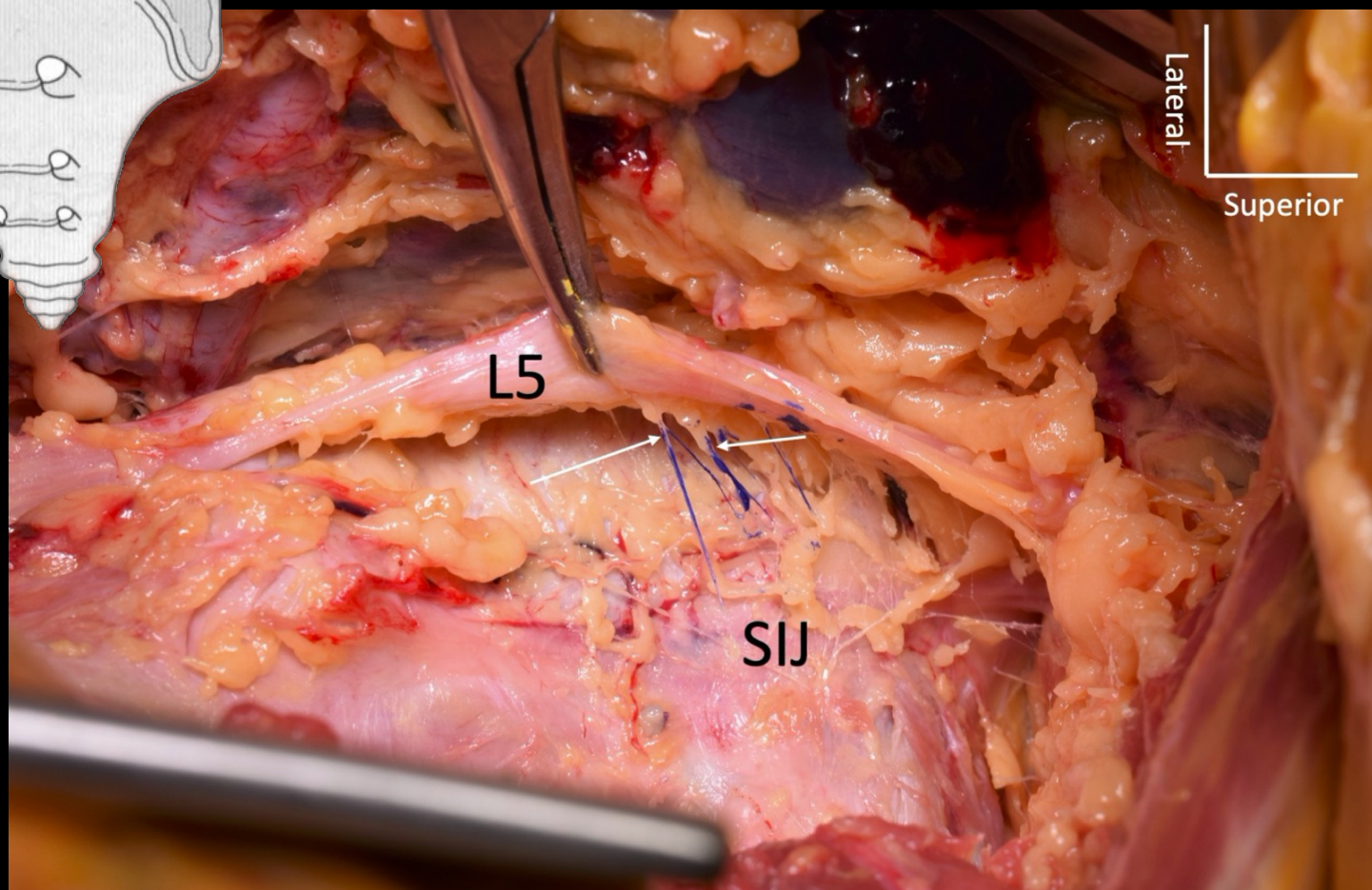
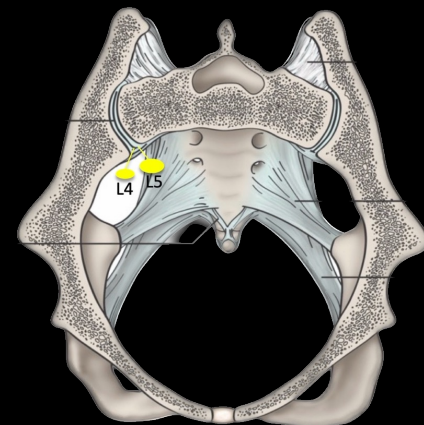
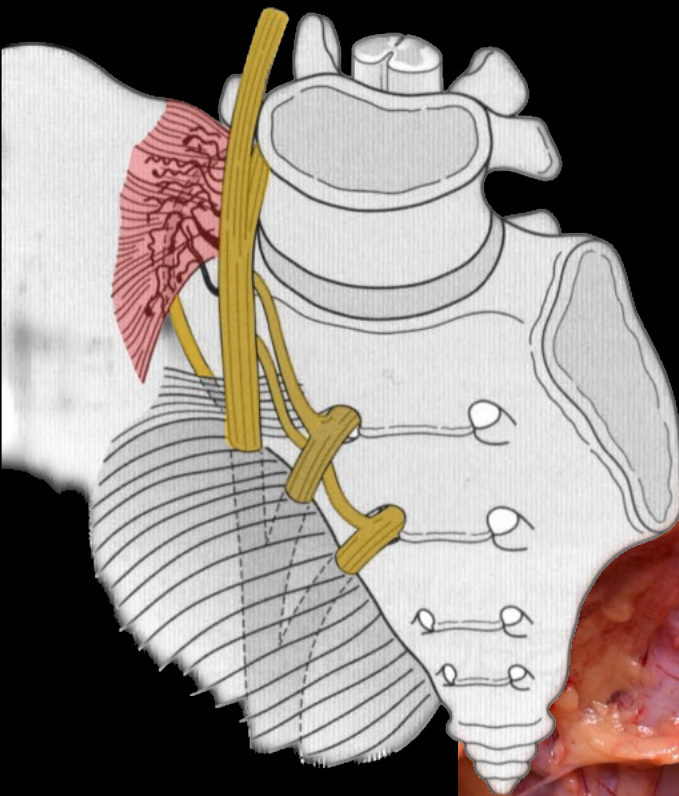
6. N. Ischiadicus

7. N. Pudendus

Anterior SI	L3	L4	L5	S1	S2	N. Glutealis Sup.	Plexus Sacralis
Solonen (1957)							
Ikeda (1991)							
Szadek (2008)							
Cox (2017)							

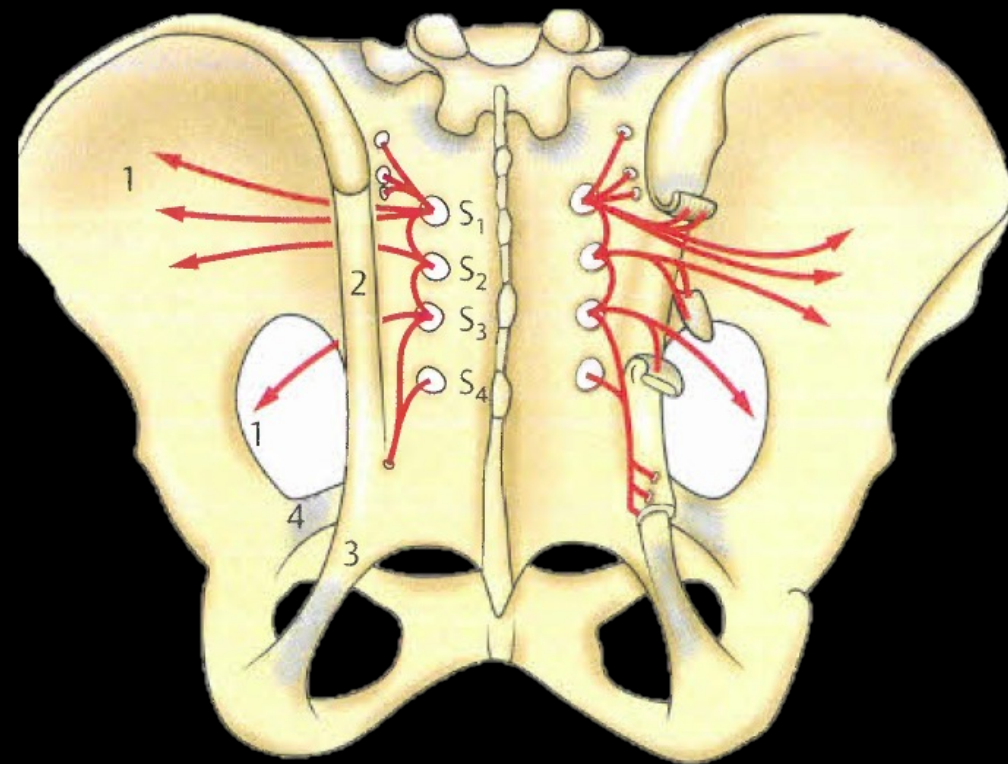
Posterior SI	N. Glutealis Sup.	L5	S1	S2	S3	S4
Horwitz (1939)						
Solonen (1957)						
Bradley et al (1974)						
Ikeda (1991)						
Grob et al (1995)						
Fortin et al (1999)						
Yin et al (2003)						
McGrath og Zhang (2005)						
Cox og Fortin (2014)						
Roberts et al (2014)						

Poilliot AJ et al. A systematic review of the normal sacroiliac joint anatomy and adjacent tissue for pain physicians. *Pain Physician* 2019; 22: E247-274



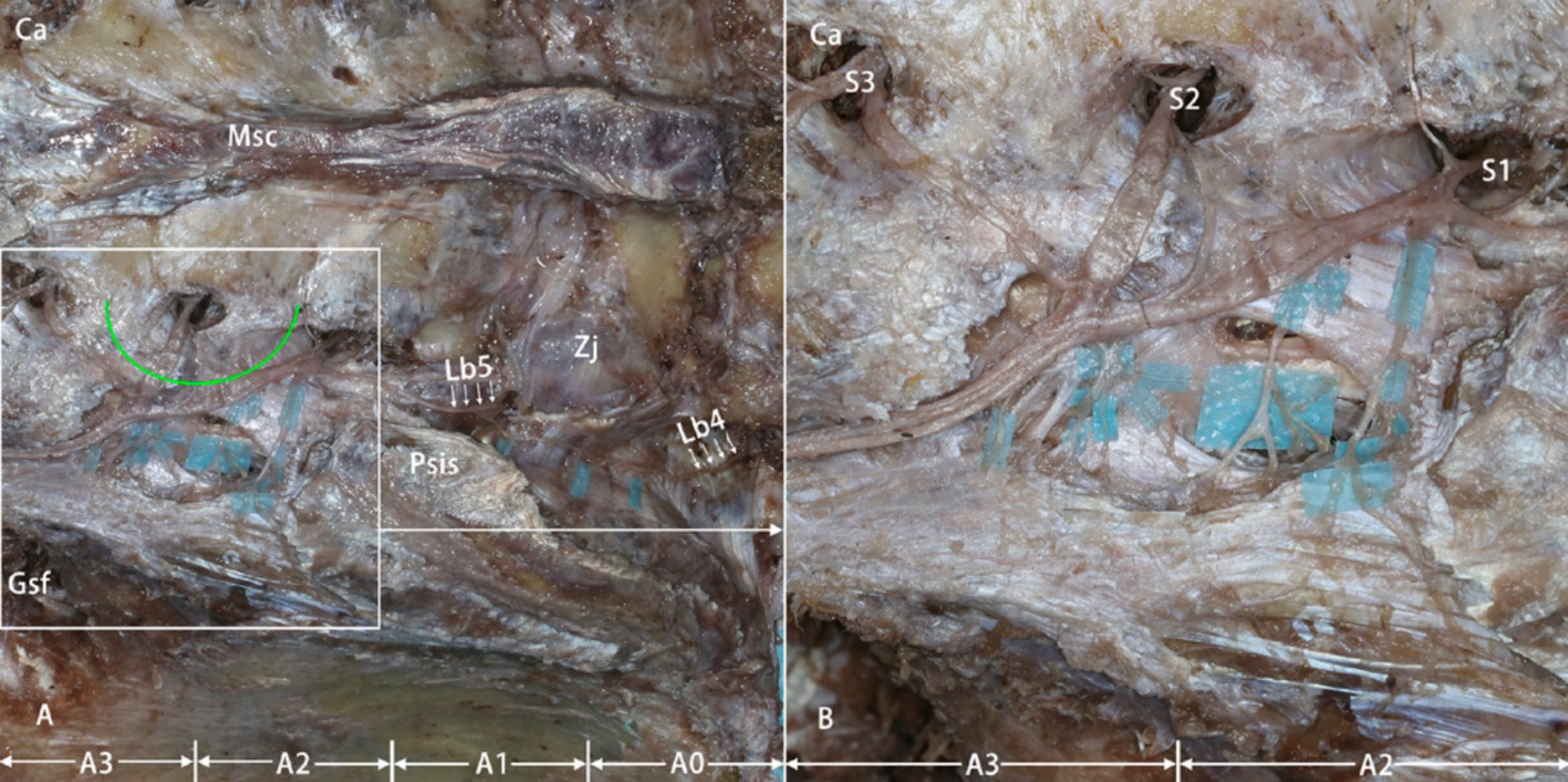
Yilmaz E et al. Are the
nerves supplying the
anterior sacroiliac joint
nociceptive? *Acta
Morphologica Online*
Ahead of Print,
February 3, 2022

Innervasjon Posteriore Strukturer

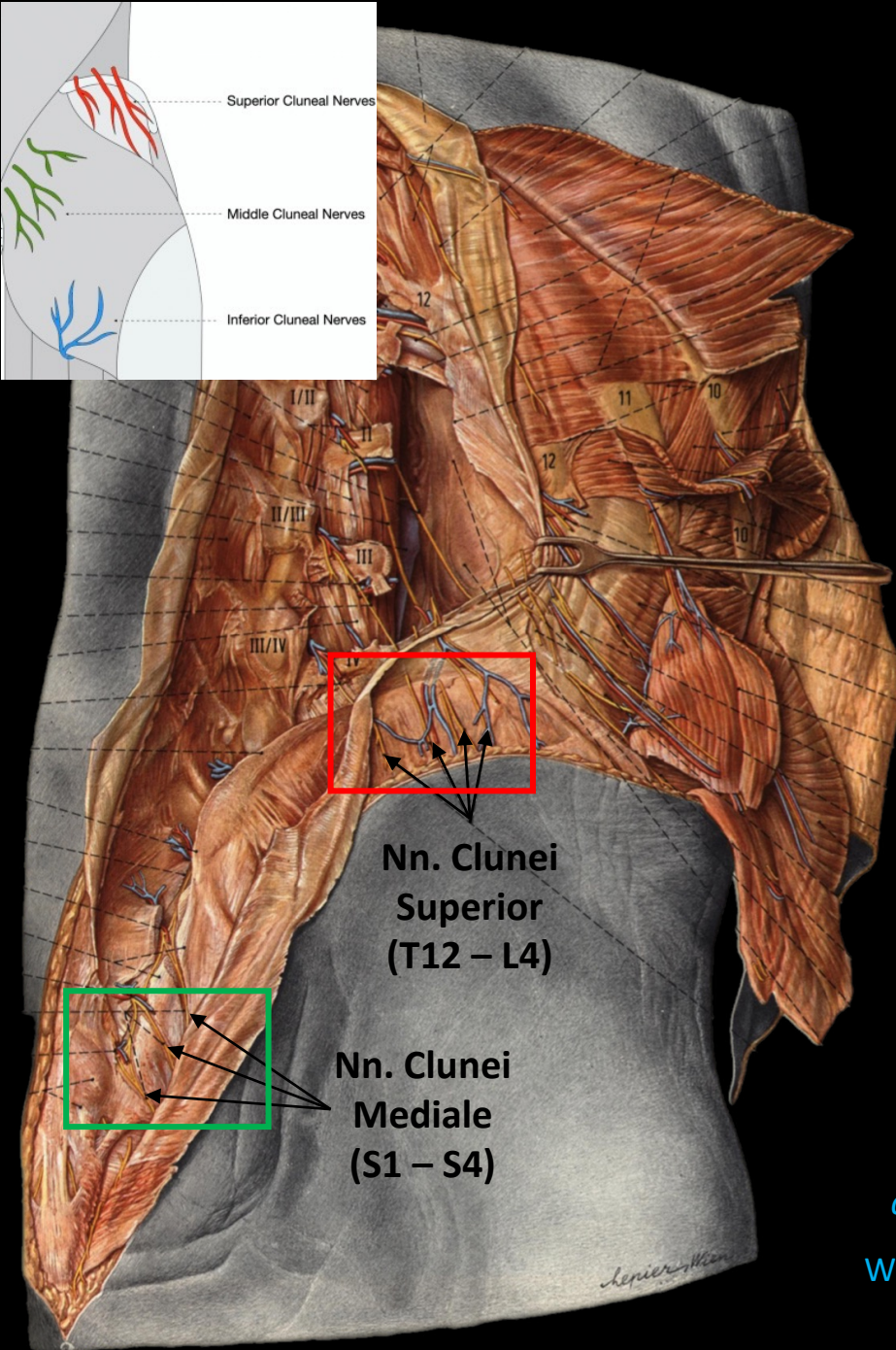
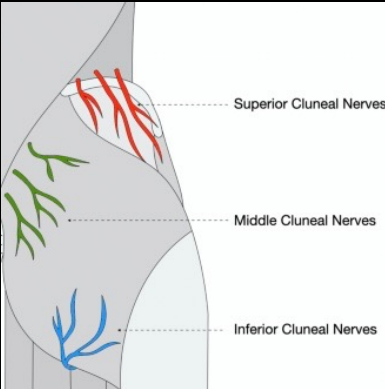


1. Nn. Clunei Mediale
2. Lig. Sacroiliacale Posterior (Longum)
3. Lig. Sacrotuberale
4. Lig. Sacrospinale

- Art. Sacroiliacale blir i det posteriore aspektet i all hovedsak innervert av S1 til S3?
- De posteriore ligamentene blir i all hovedsak innervert av S1 til S3?

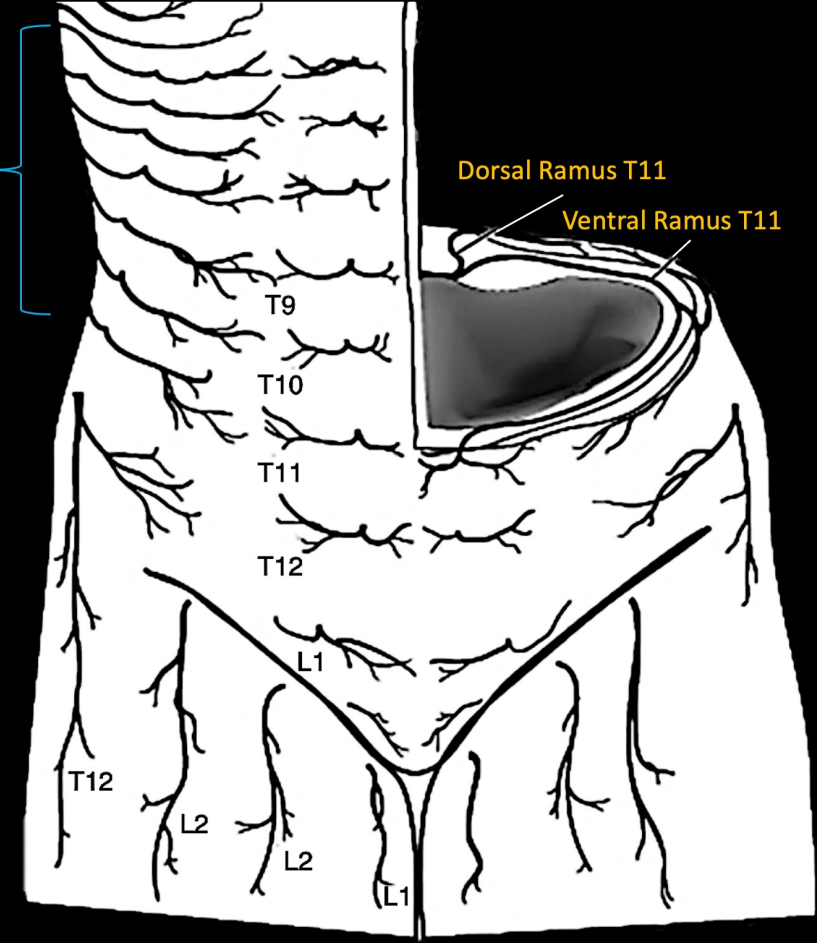


- Både lumbale (L4 og L5) og sacrale nerver bidro til innervasjon av de posteriore intrinsiske ligamentene tilknyttet SI – Leddet.
- Det ble observert anastomoser mellom grener fra L5 og alle Nn. Sacrales i denne studien på en pleksus-lignende måte i alle tilfeller



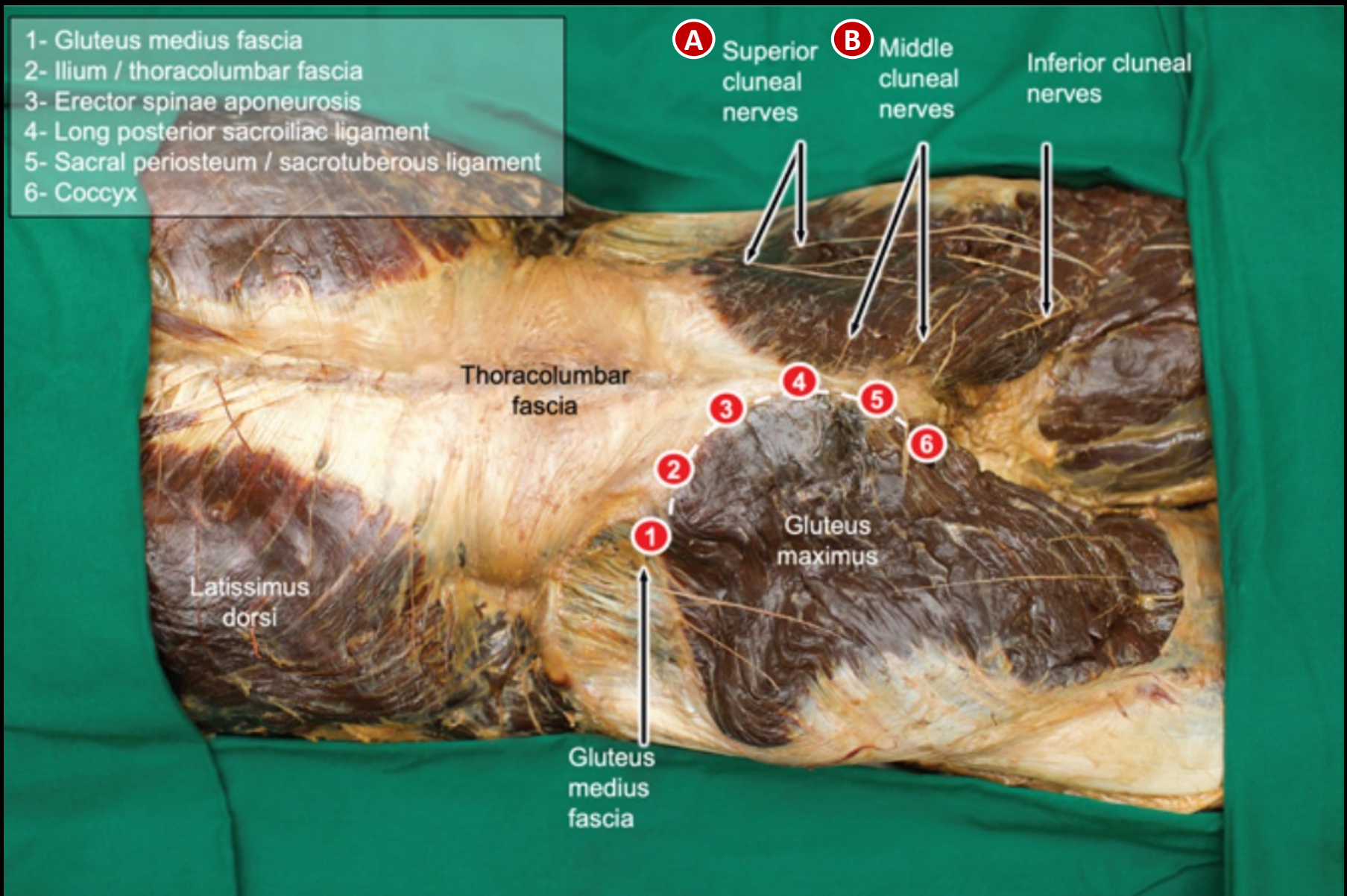
Thoracoabdominal Nerves

Lateral Branch of T12




Pernkopf E. *Atlas D'Anatomie Humaine: Tome II Thorax, abdomen et membres*. Paris / Padova: Editions PICCIN 1983

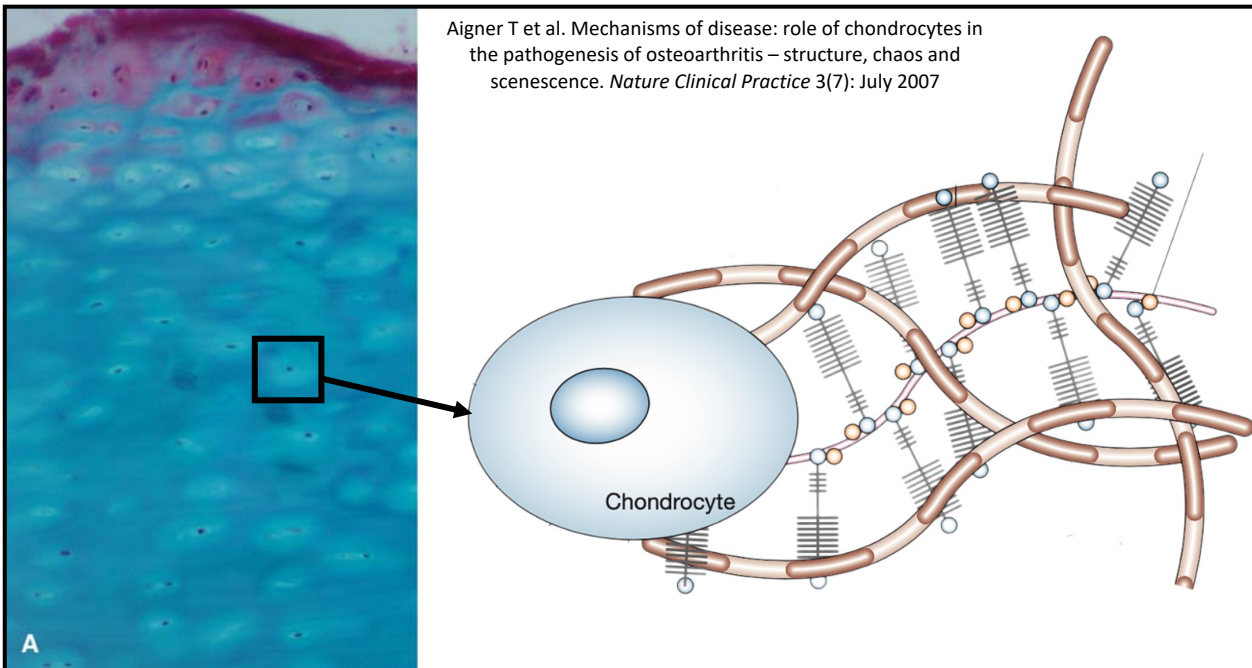
Willard FH, Schuenke MD. Neuroanatomy of female pelvic pain. In: Bailey A (ed): *Pain in women*. Heidelberg: Springer 2013



Hammer N (Ed.). *The obscure sacroiliac joint: insights into anatomy, biomechanics, etiology and the treatment of mechanical dysfunction*. London: CRC Press Taylor & Francis 2023

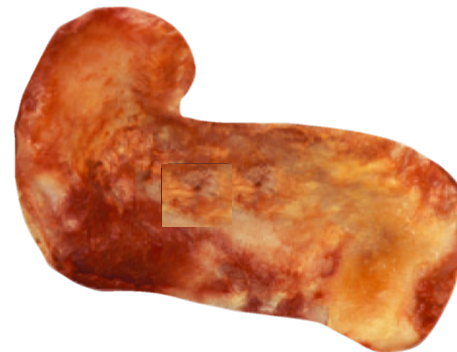
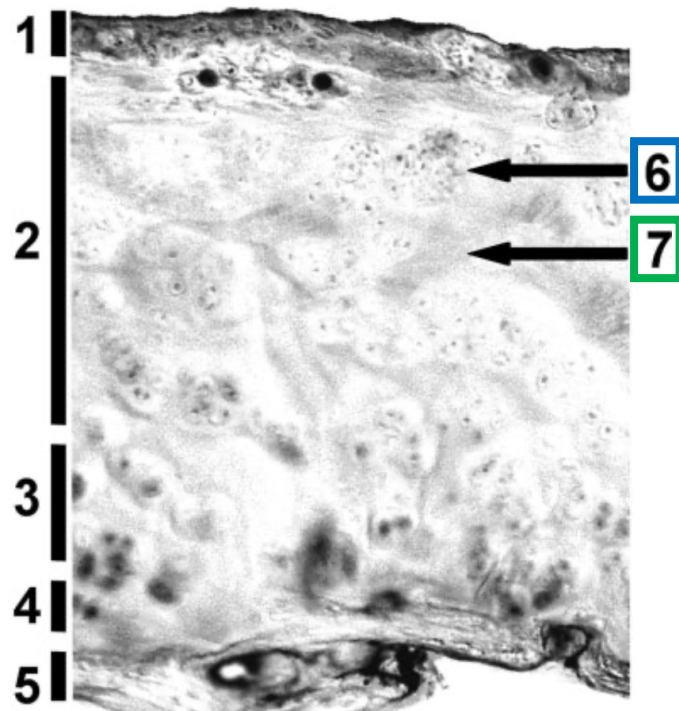
Kort om Brusken som dekker Leddflatene





Szadek KM et al. Nociceptive nerve fibers in the sacroiliac joint in humans. *Regional Anesthesia & Pain Medicine* (33)1: 36-43, 2008

- Nerve fibre i Lig. Sacroiliacale Anterior, Leddkapsel og Lig. Interossea
- Substans P, CGRP og TH



1 – 3: Brusk
 4: Kalsifisert Brusk
 5: Subchondral knokkel
 6: Chondrocytter
 7: Extracellulær Matriks

Szadek KM et al. Possible nociceptive structures in the sacroiliac joint cartilage: An immunohistochemical study. *Clinical Anatomy* 23: 192-198 (2010)

- Immunoreaktivitet hos chondrocytter
- Substans P og CGRP

A historical map of a city, likely from the 17th or 18th century, showing a grid street pattern and fortifications. The map is titled 'No 2' in the top left corner. The city is surrounded by a wall with bastions. The map is oriented with North at the top. The title 'Ligamenter: Art. Sacroiliacale' is overlaid on the map in large white text.

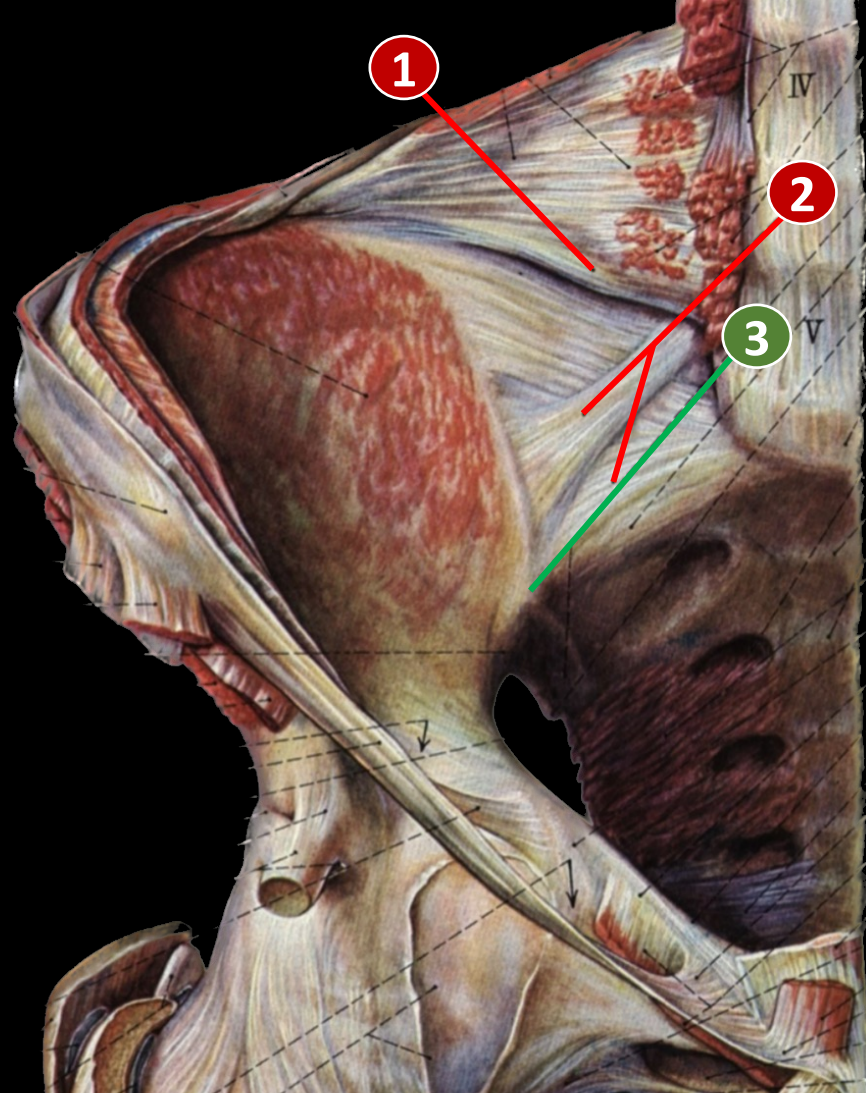
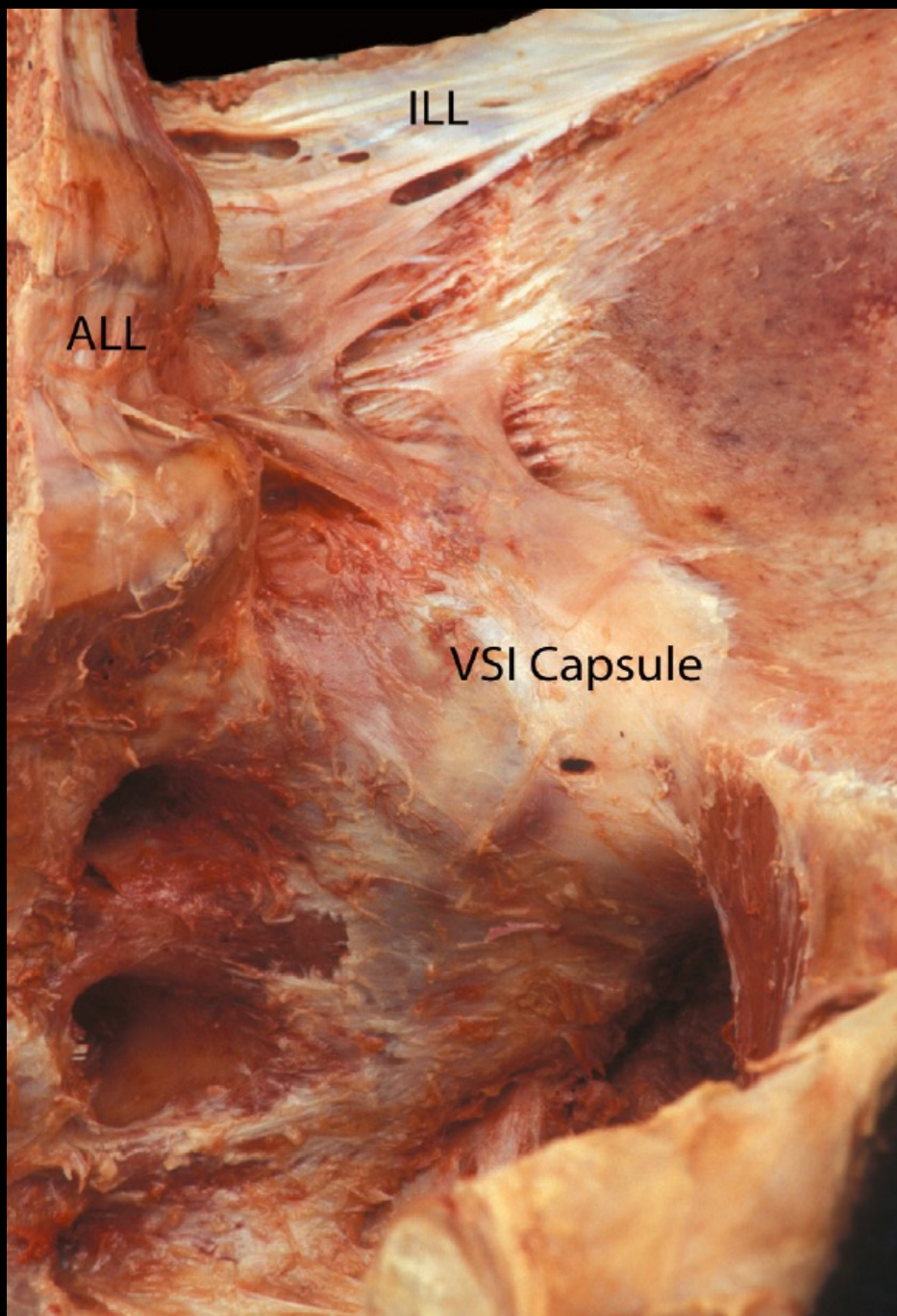
Ligamenter: Art. Sacroiliacale

Intrinsiske

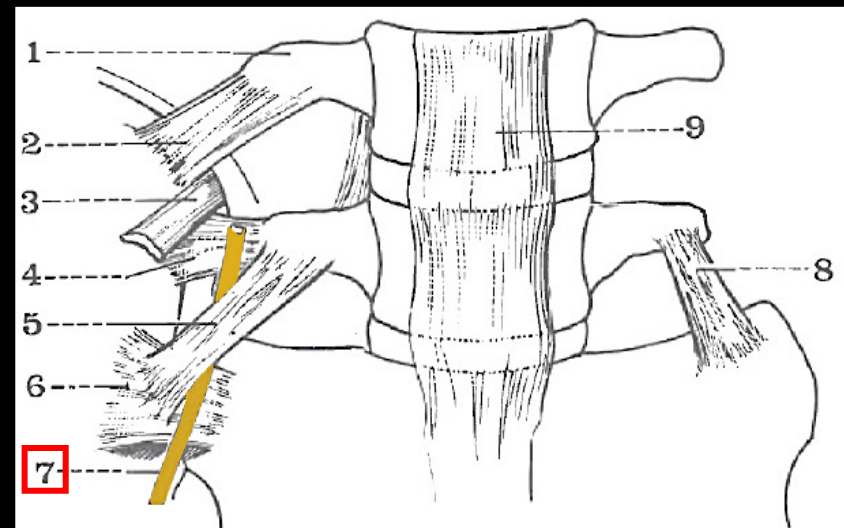
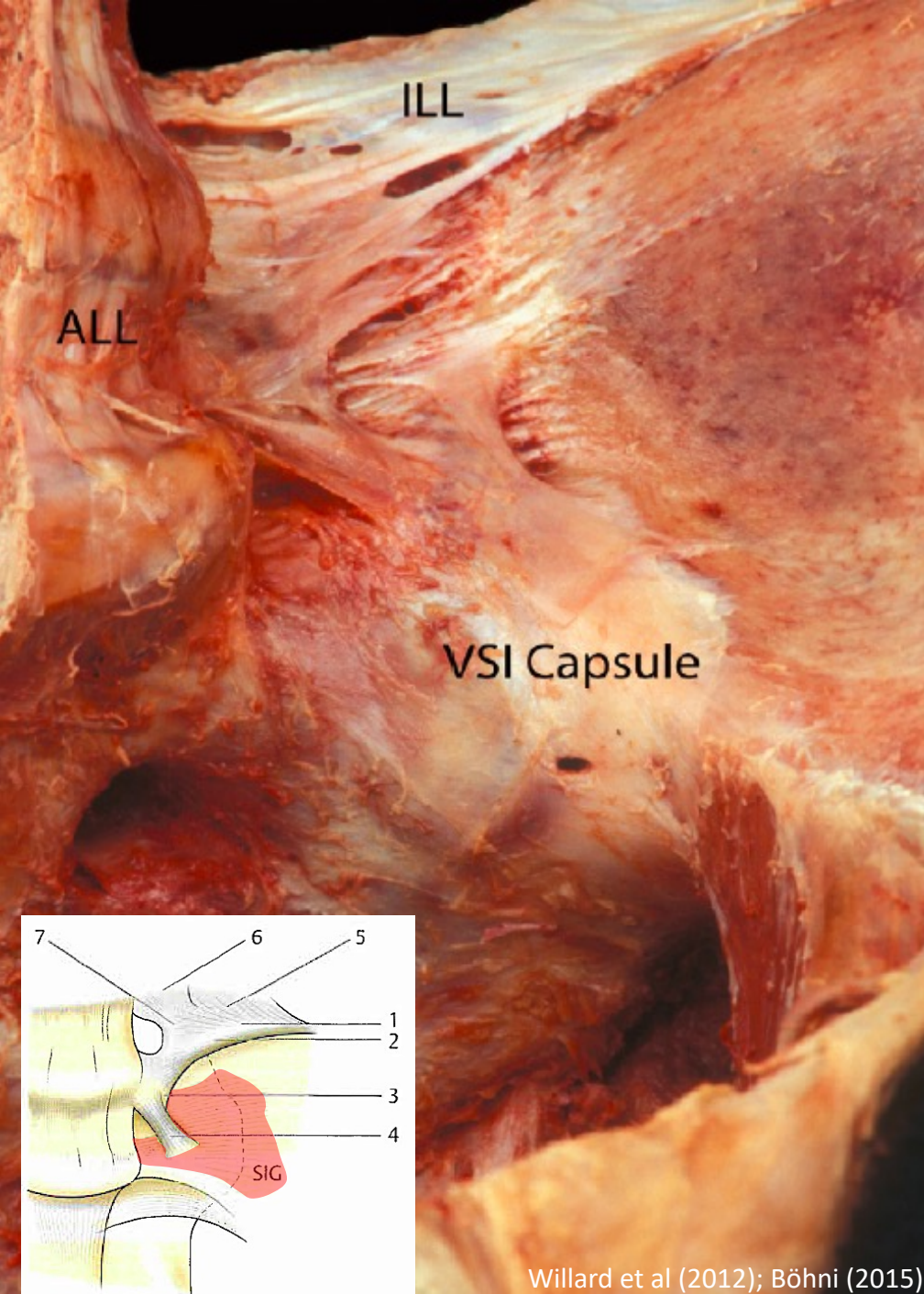
- Lig. Sacroiliacale Anterior og Posterior, Lig. Interossea

Ekstrinsiske

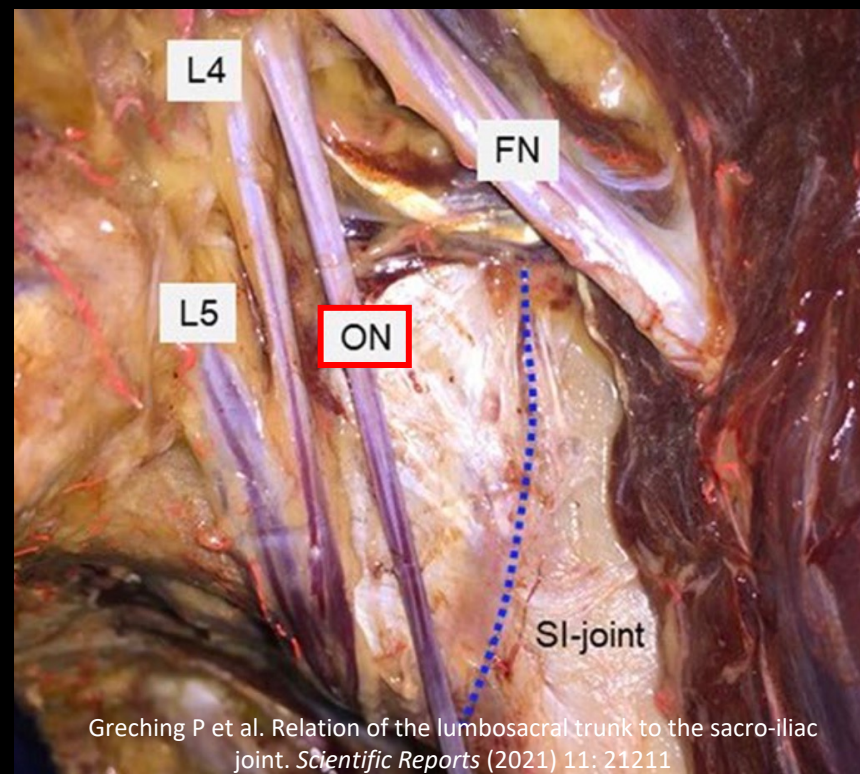
- Lig. Iliolumbale, Lig. Sacrotuberale, Lig. Sacrospinale



1. Lig. Iliolumbale
2. Lig. Sacroiliacale Anterior
3. Art. Sacroiliacale

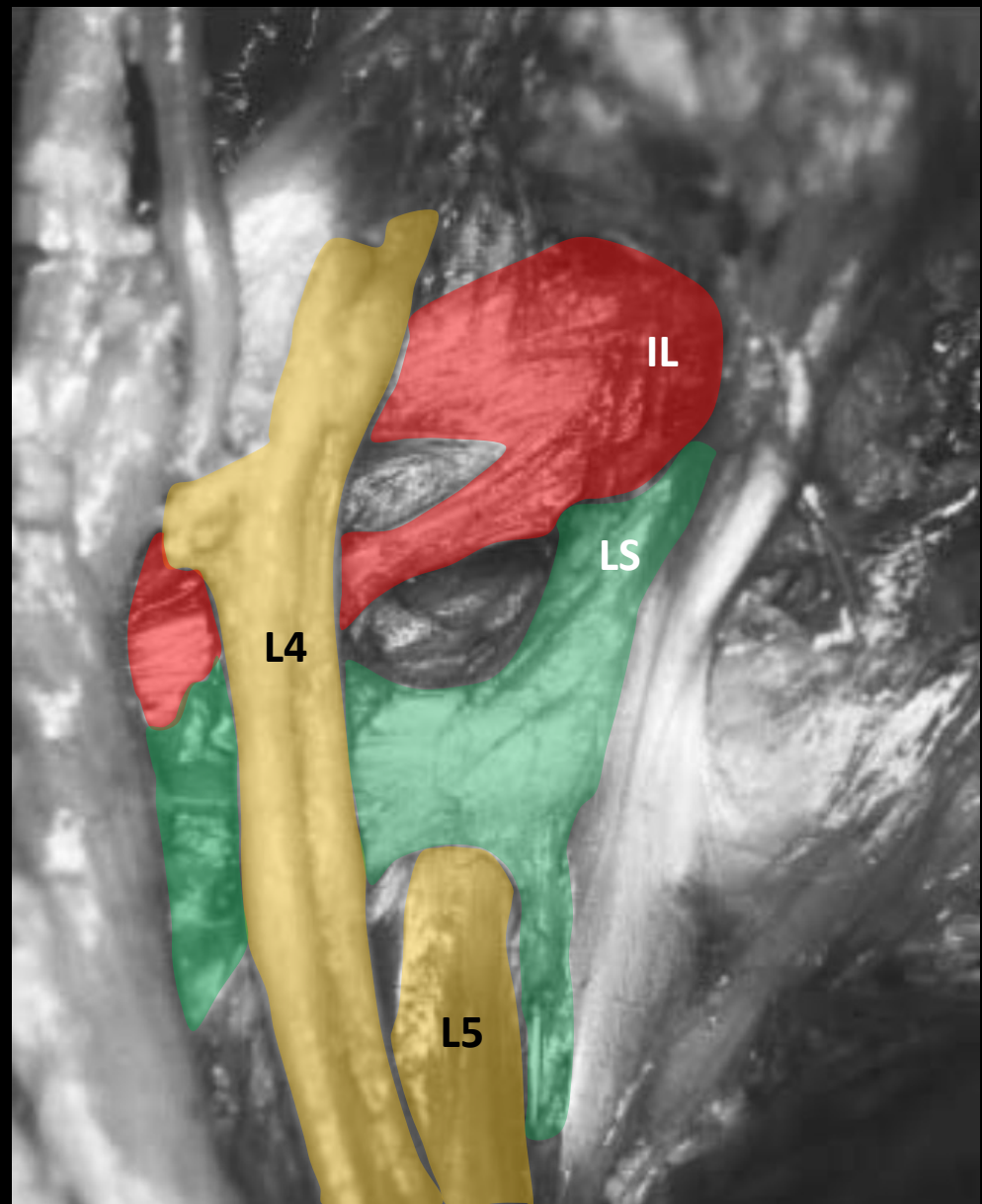
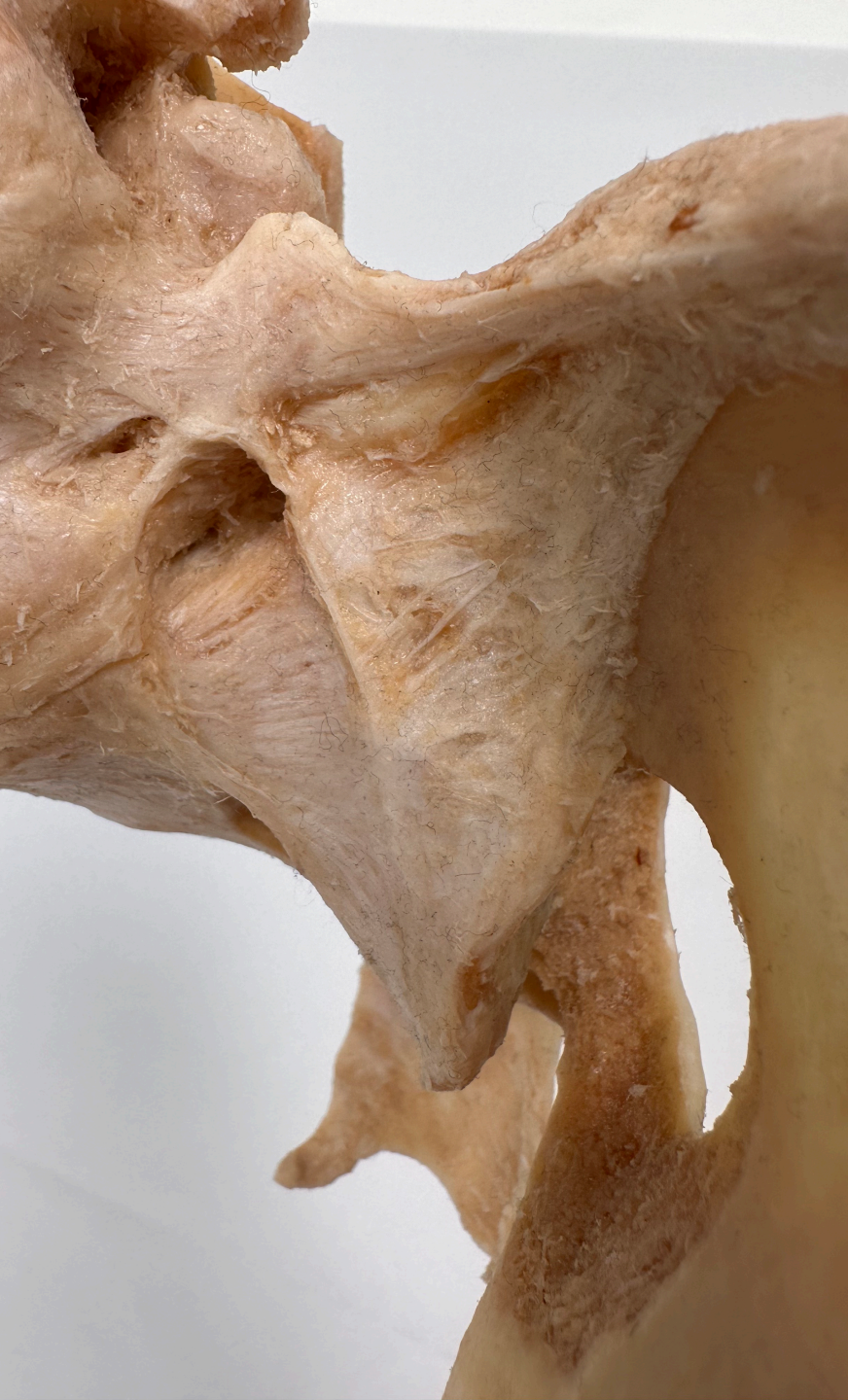

Bouchet A, Cuilleret J. *Anatomie topographique descriptive et fonctionnelle: Tome 4*. Paris: SIMEP Masson 2001



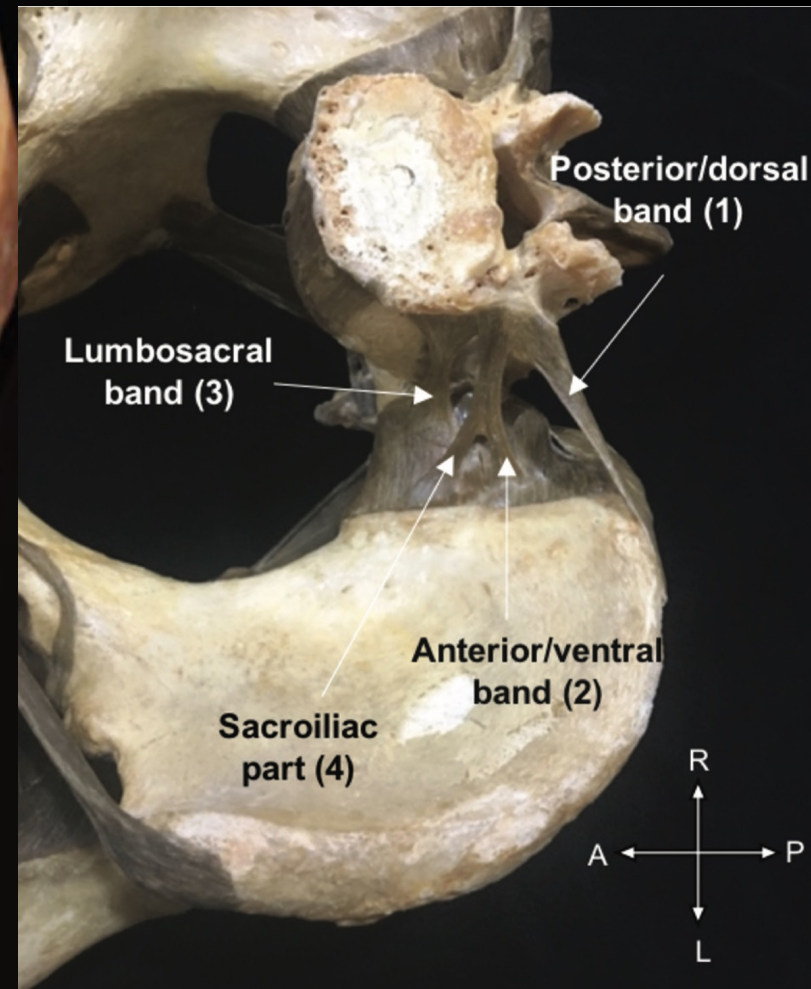
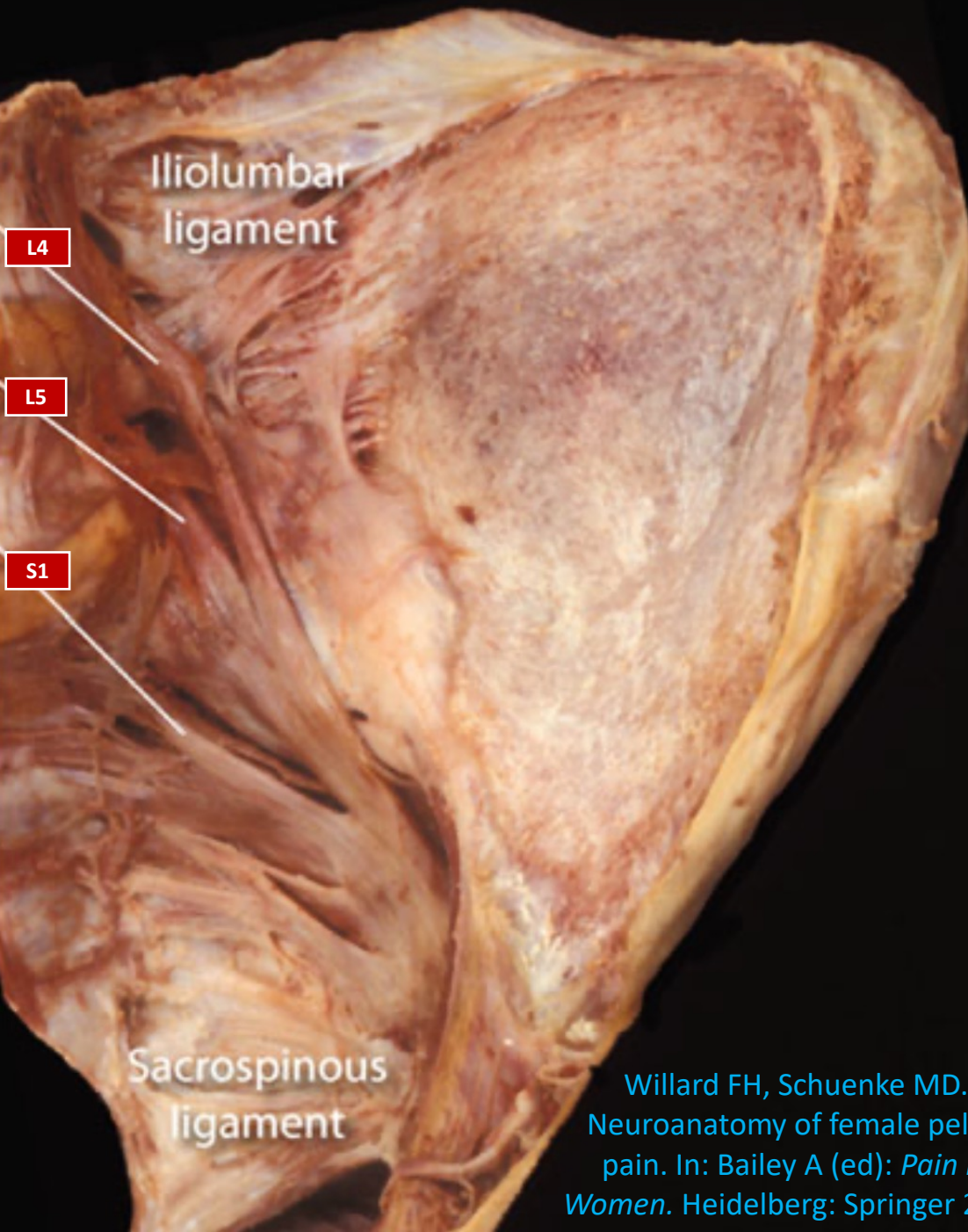
Greching P et al. Relation of the lumbosacral trunk to the sacro-iliac joint. *Scientific Reports* (2021) 11: 21211

Willard et al (2012); Böhni (2015)



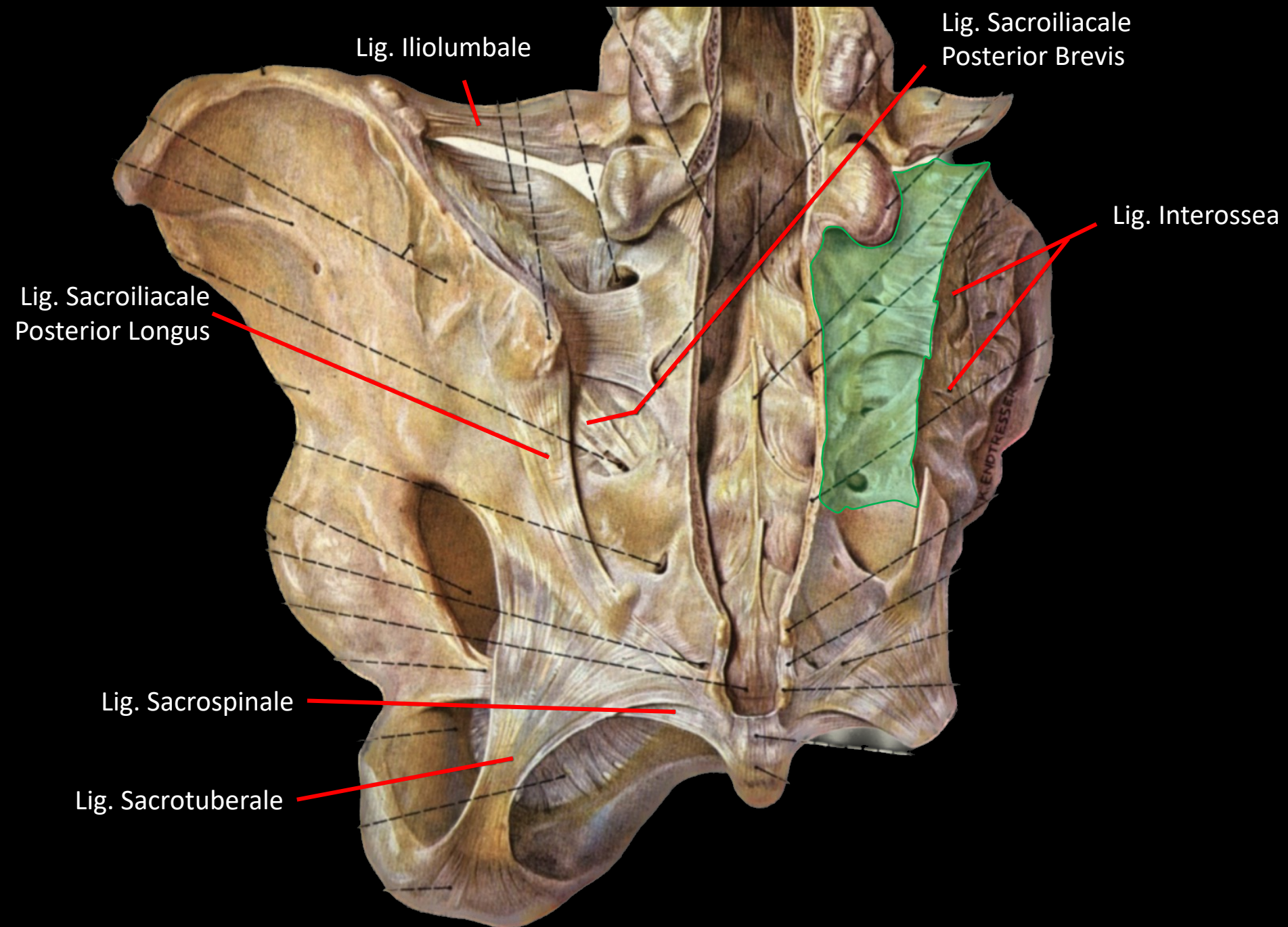
Kleihues H et al. Topographical relations between the neural and ligamentous structures of the lumbo-sacral junction: in-vitro investigation. *Eur Spine J* (2001) 10: 124 - 132

Lig. Iliolumbale



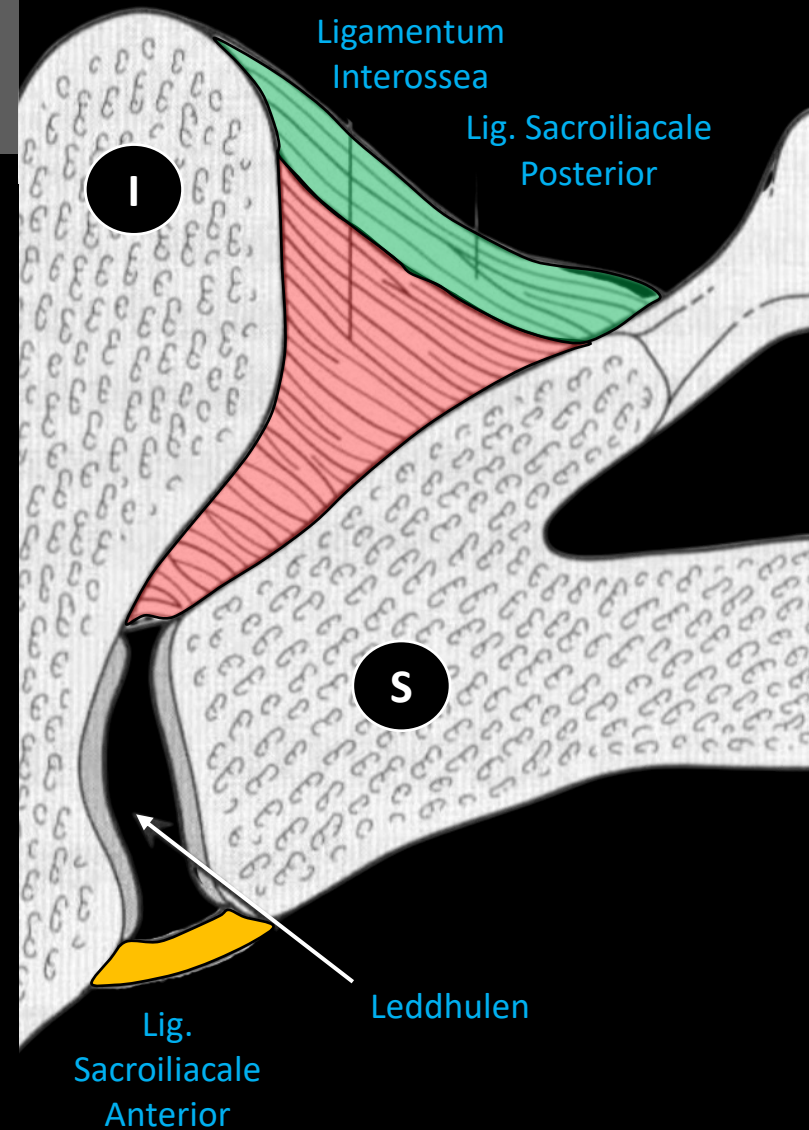
Willard FH, Schuenke MD.
Neuroanatomy of female pelvic
pain. In: Bailey A (ed): *Pain in
Women*. Heidelberg: Springer 2013

Poilliot AJ et al. A systematic review of the
normal sacroiliac joint anatomy and adjacent
tissue for pain physicians. *Pain Physician* 2019;
22: E247-274

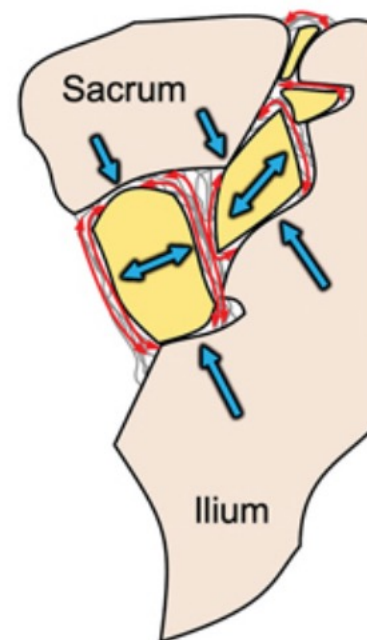
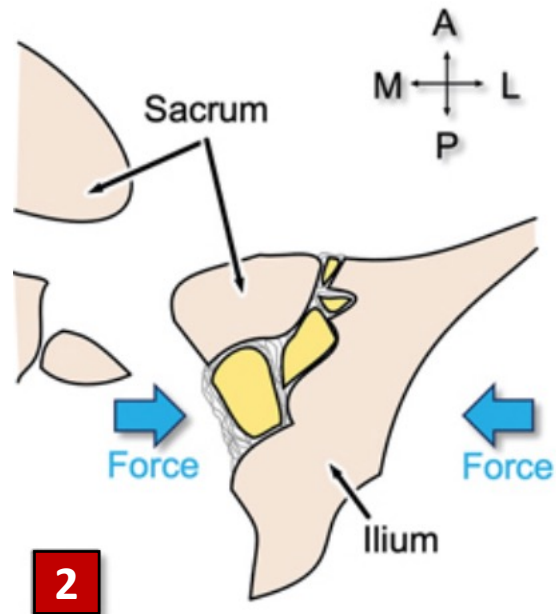
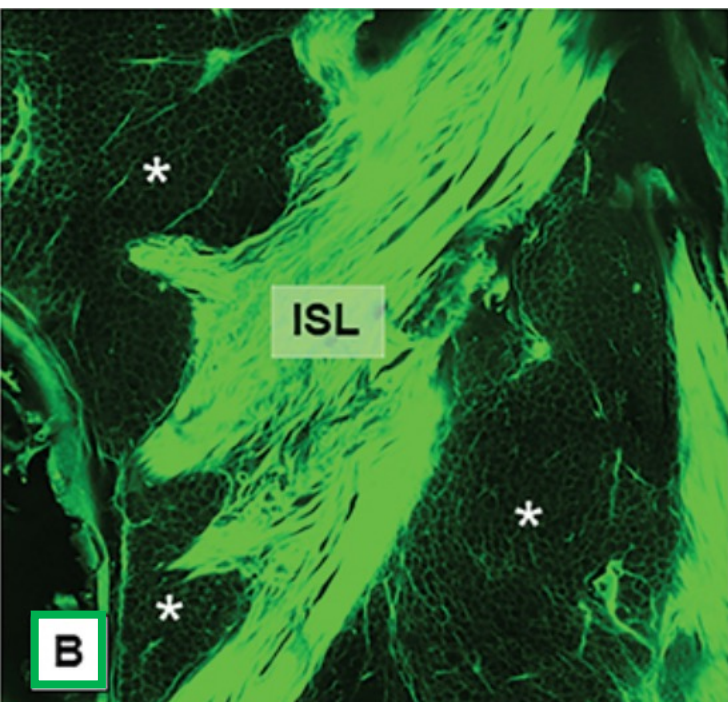
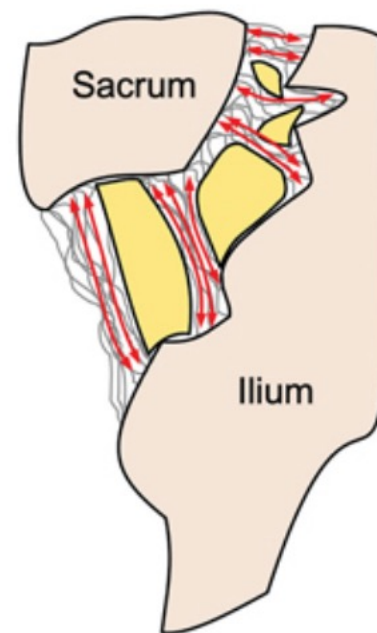
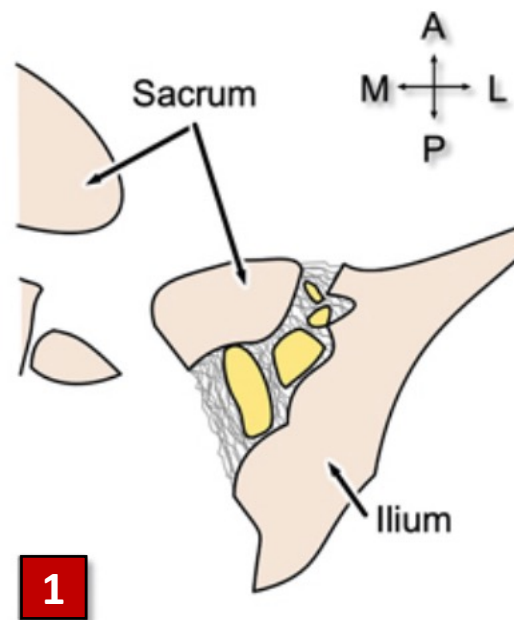
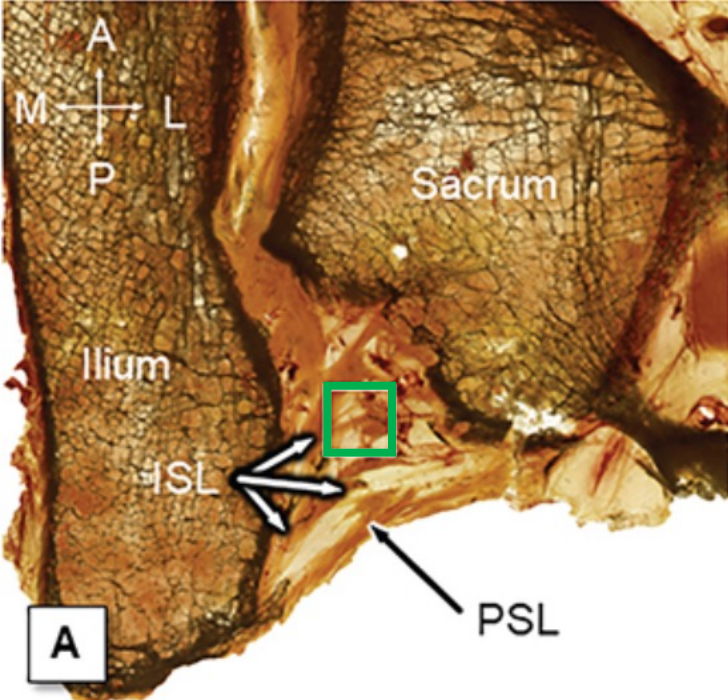


Intrinsiske Ligamenter

- **Lig. Sacroiliacale Anterior**
 - Tynt ligament som forsterker leddkapselen
 - Innervasjon for nocicepsjon
- **Lig. Sacroiliacale Posterior**
 - Sterkt ligament som er viktig for stabilisering
 - Tett relasjon til flere grener av Nn. Sacralis
 - Innervasjon for nocicepsjon
- **Lig. Interossea¹**
 - Mye løst bindevev,
 - rikelig med adipocytter og blodkar
 - Kollagen <30%
 - Adipocytter 13.5%
 - Blodkar 2%
 - Grunnsustans 55%

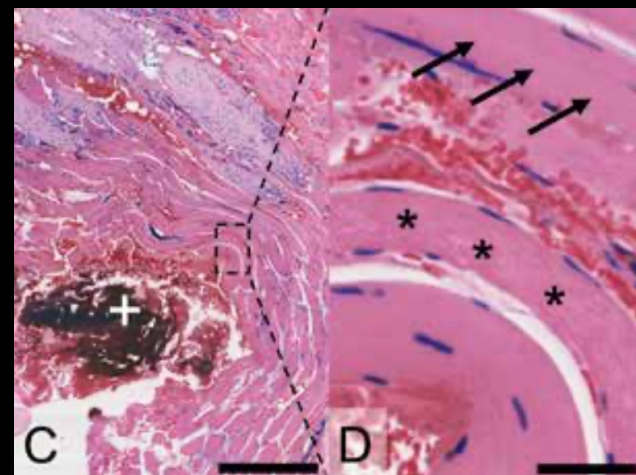
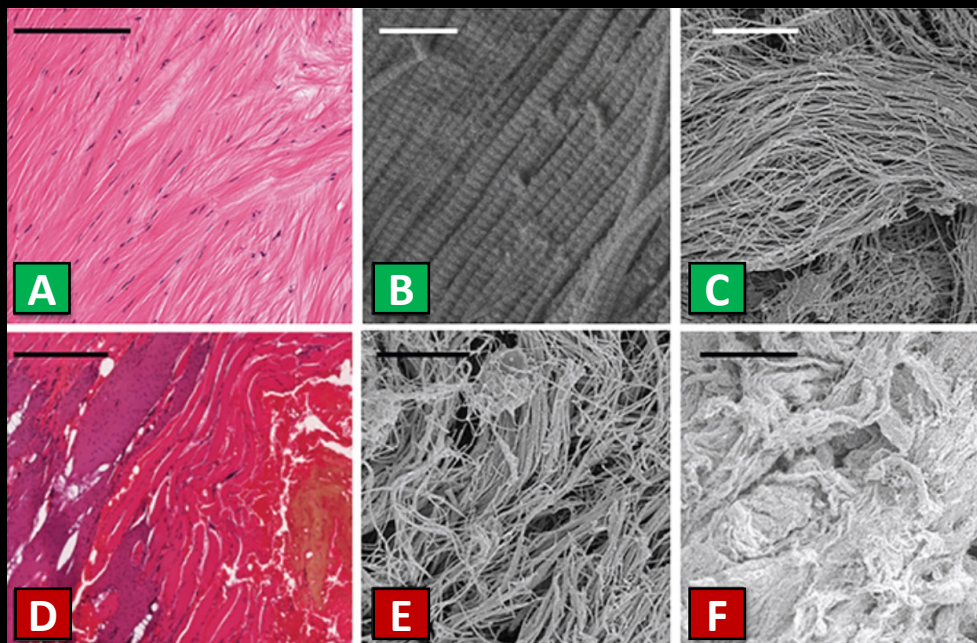


¹Bechtel R. Physical characteristics of the axial interosseous ligament of the human sacroiliac joint. *The Spine Journal* 1(2001): 255 - 259

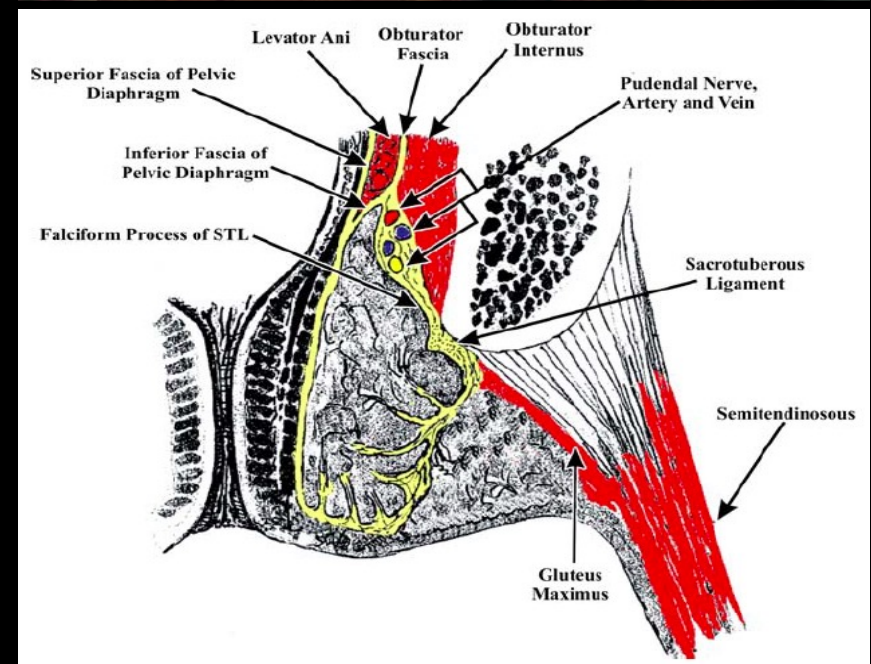
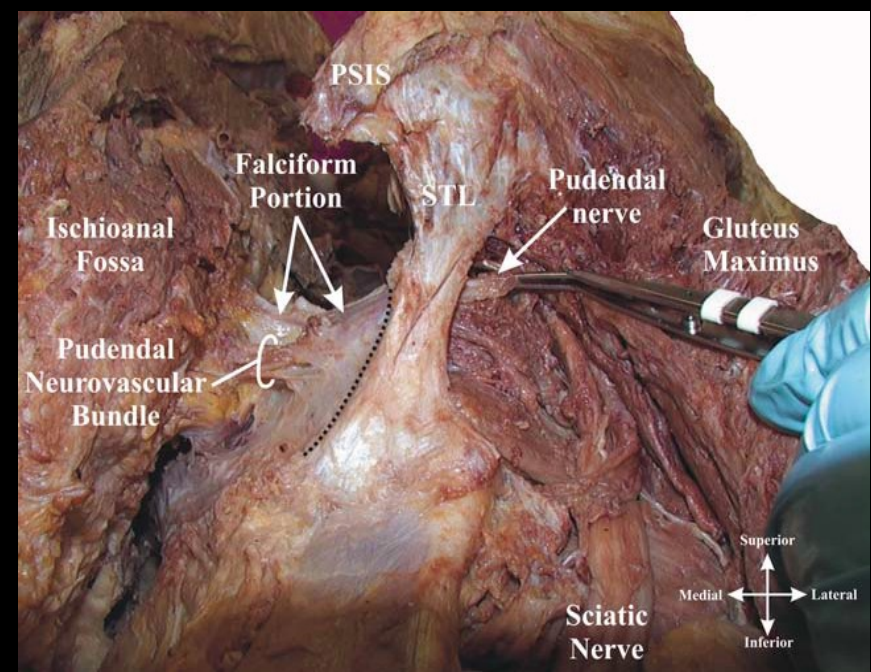
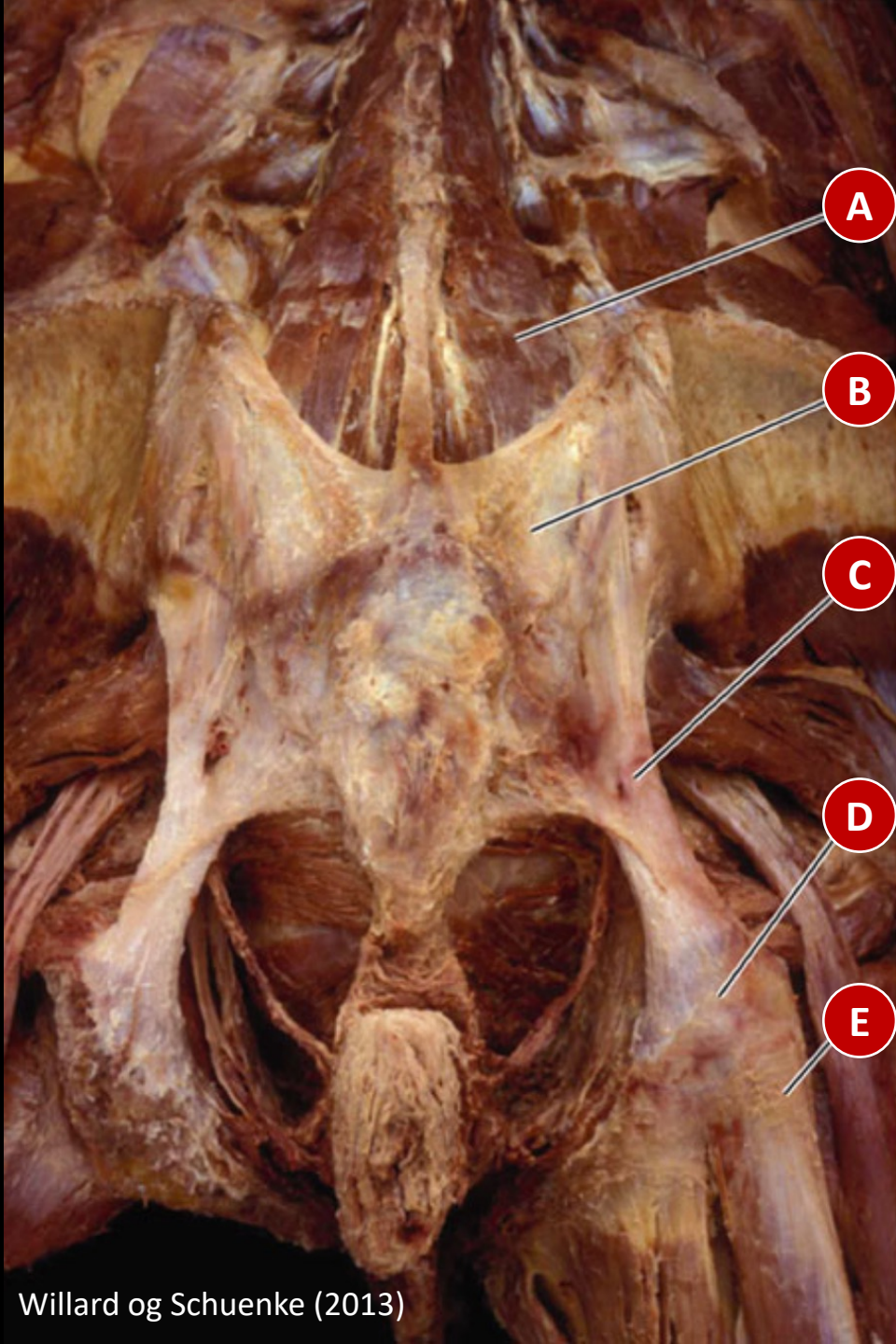


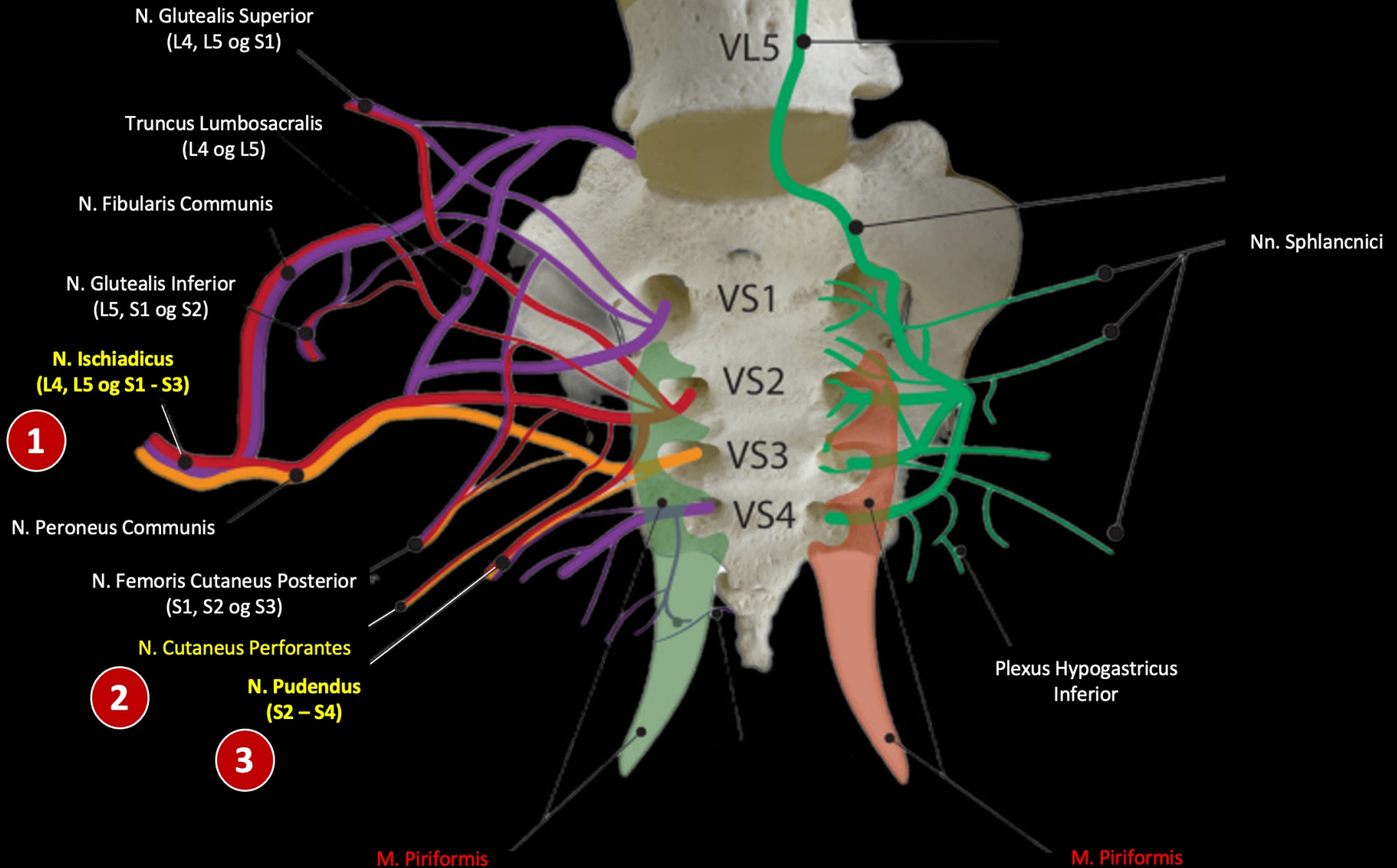
Hvis vi aksepterer rikelig med innervasjon til de intrinsiske SI ligamentene, kan vi og beskrive patofysiologiske endringer i de?

- Ligamentær insuffisiens vil endre måten belastning distribueres gjennom bekkenringen
- Nylig har også morfologiske endringer i de intrinsiske ligamentene vært dokumentert som følge av mikrotraumer, i all hovedsak Lig. Interossea og Lig. Sacroiliacale Posterior
- De mikroskopiske funnene inkluderer vaskularisering, blødninger, disorganisasjon av kollagen og kollagen degenerering

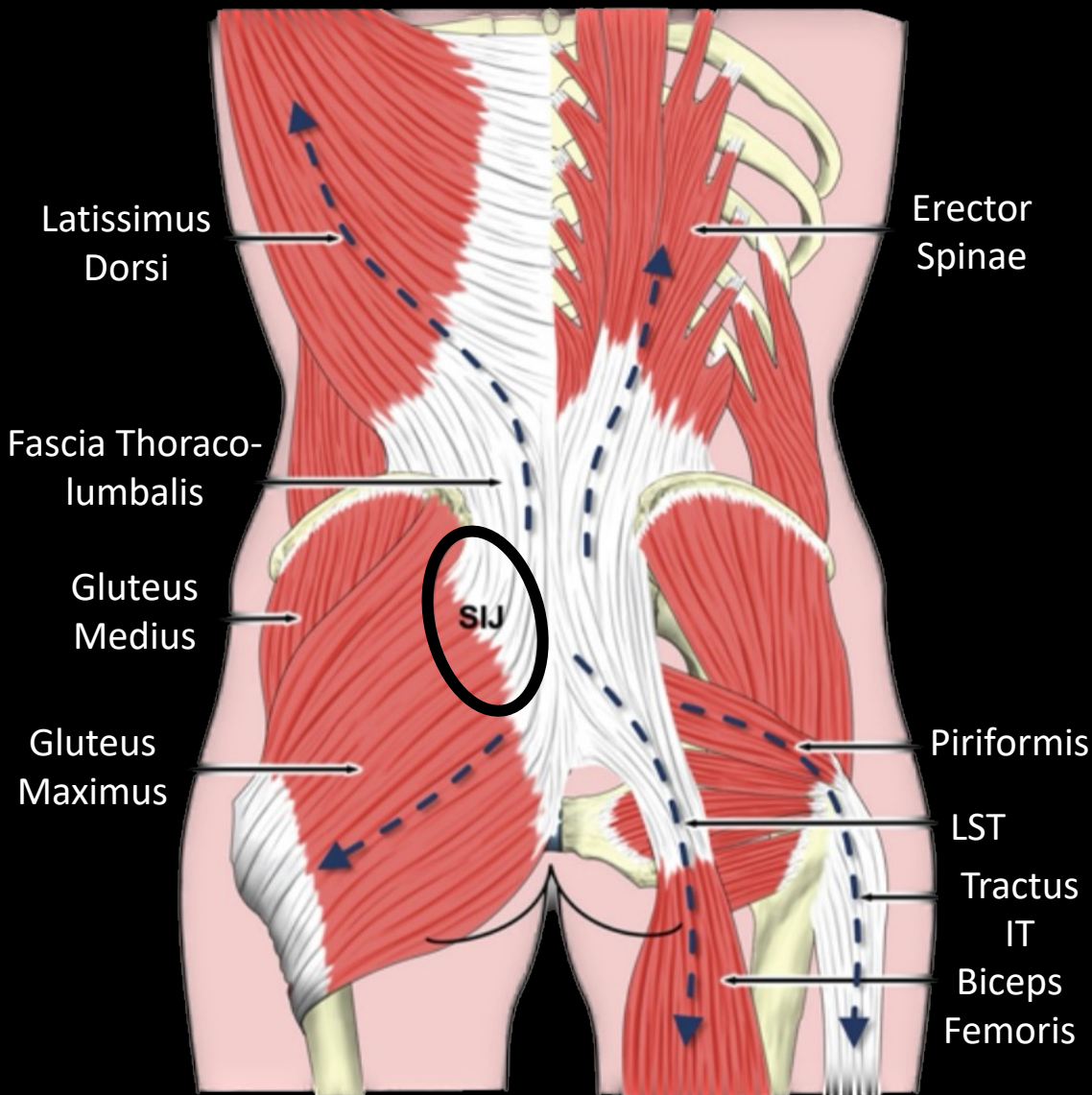


Hammer N et al. Sacroiliac joint ligaments and sacroiliac pain: a case-control study on micro- and ultrastructural findings on morphologic alterations. *Pain Physician* 2019; 22: E615-625



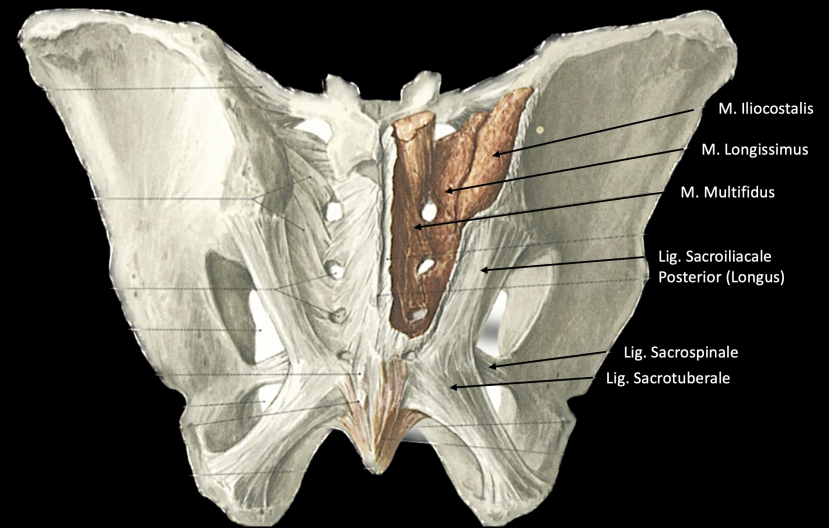
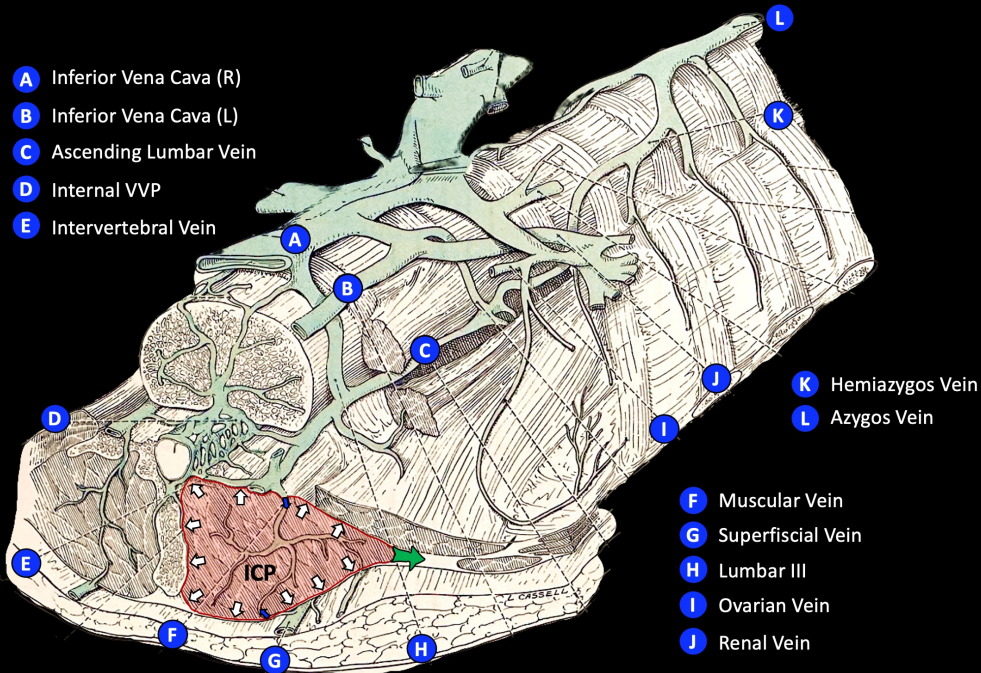
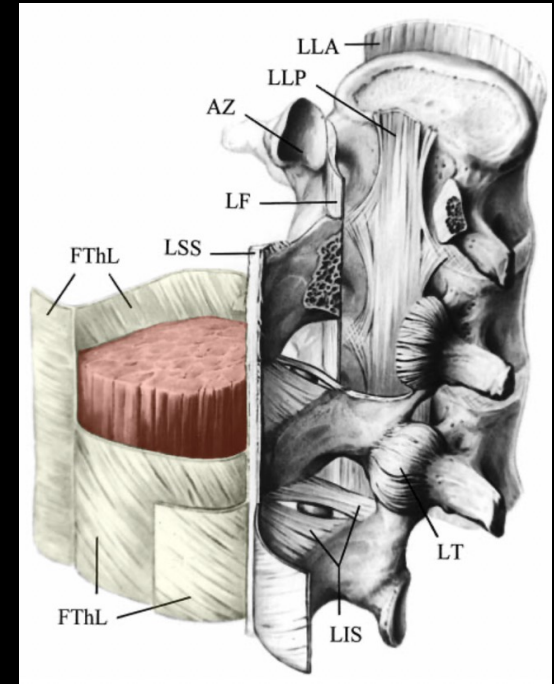
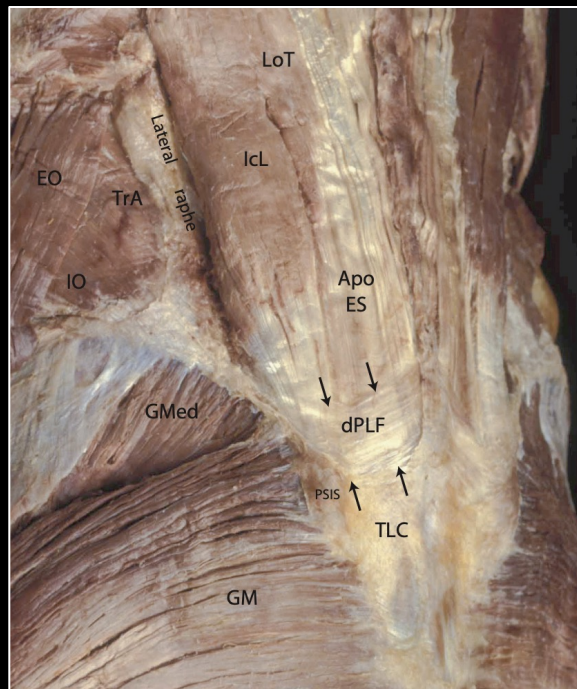
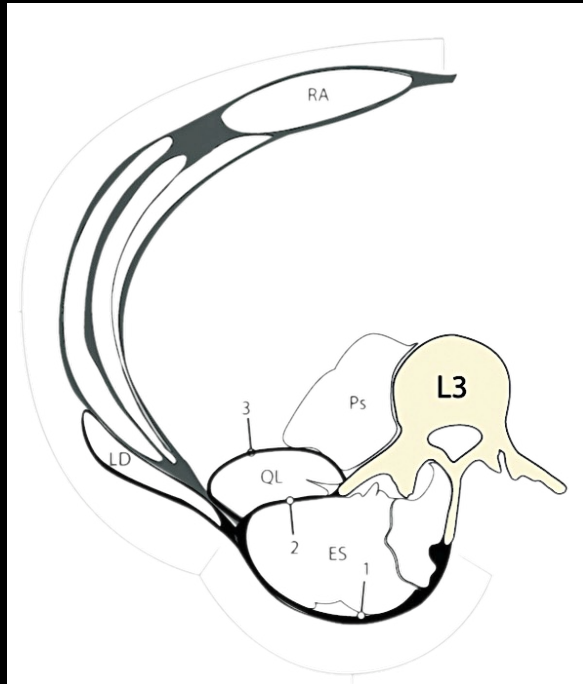


Muskulatur med forbindelser til Posteriole Ligamenter



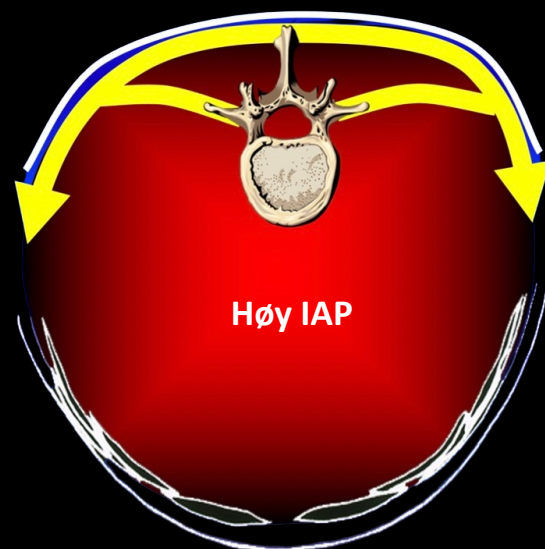
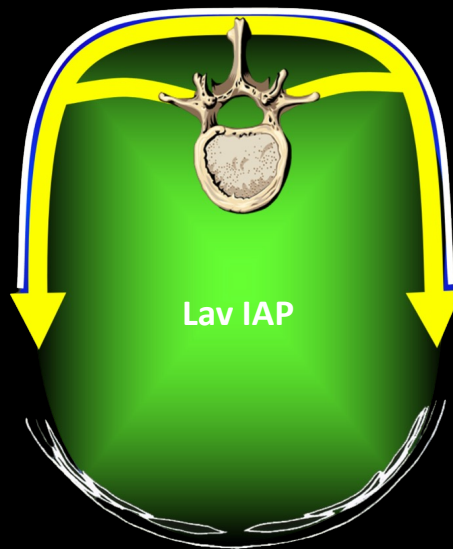
Myofascielle Strukturer som Bidrar til «Kraftslutt» i Sacroiliac Leddet

- Fascia thoracolumbalis
- Endopelvicale Fascier
- Latissimus Dorsi
- Psoas Major
- Quadratus Lumborum
- Erector Spinae
- Multifidus
- Gluteus Maximus
- Gluteus Medius
- Coccygeus
- Piriformis
- Biceps Femoris
- Semimembranosus
- Semitendinosus
- Transversus Abdominis
- Obturator internus



Willard et al (2012); Lierse (1987); Anson (19872); Graichen og Putz (1999)


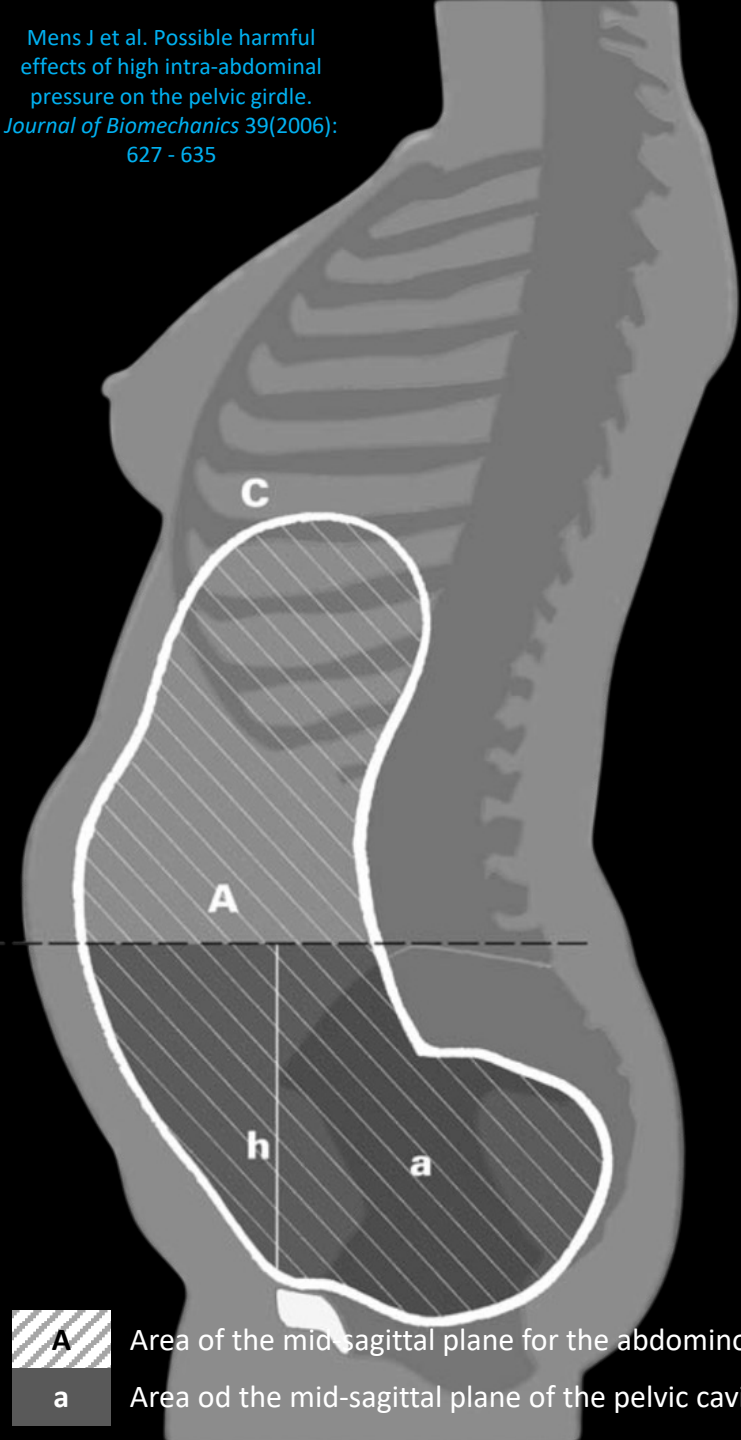
Intra-Abdominelt Trykk (IAP)



Belasting indusert av IAP på Bekkenringen*	
Flat Abdomen	Oppblåst Abdomen
ADL: 26 – 135 N	ADL: 32.3 – 268 N
Anstrengelse: 104 – 520 N	Anstrengelse: 129 – 645 N

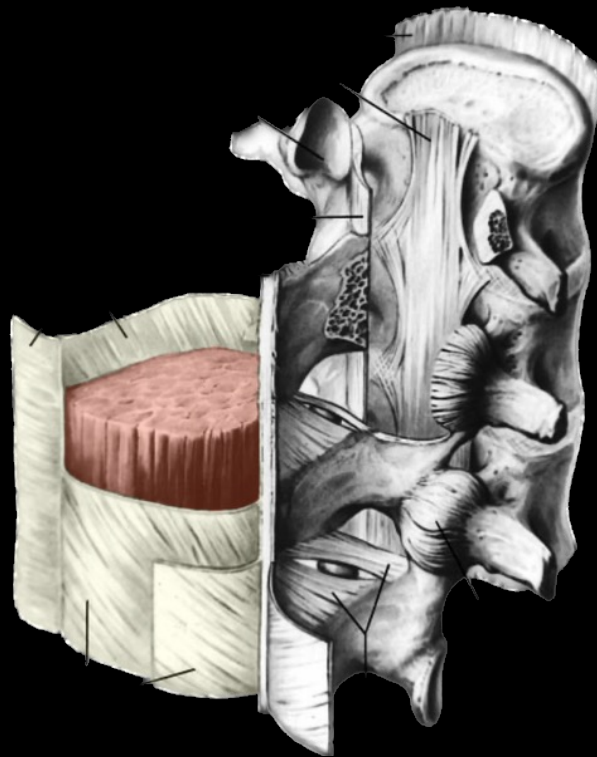
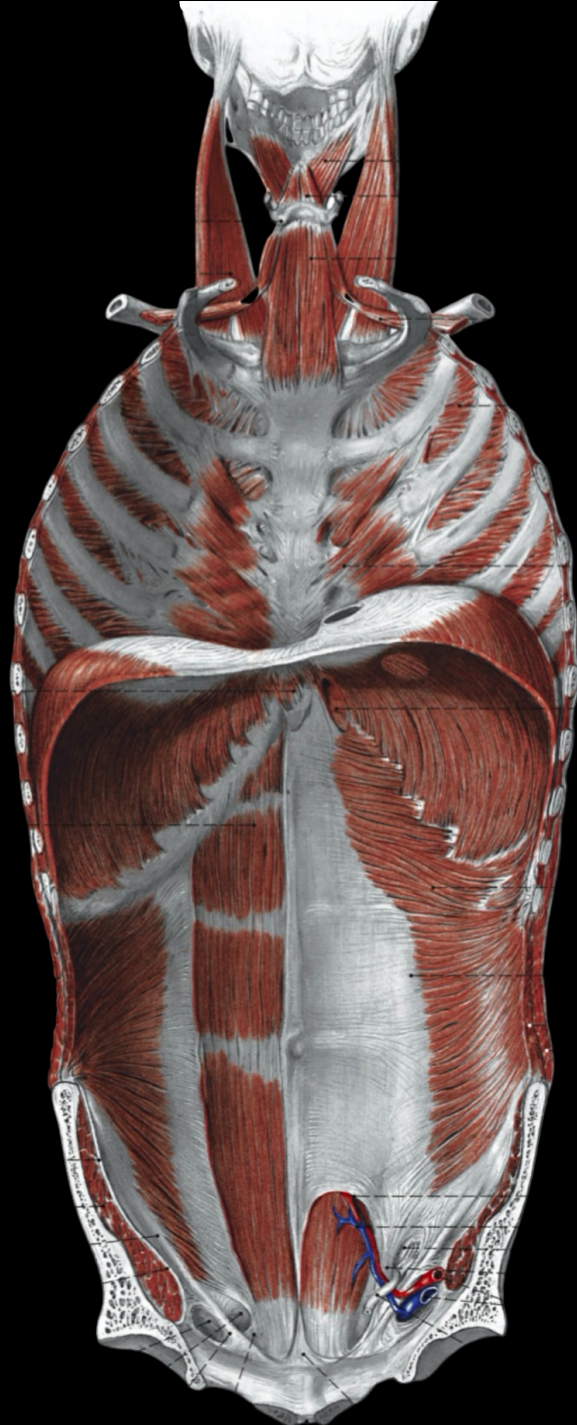
*SI – belte avlaster smerter med kraft på 100 N. IAP kan overgå dette

Økt IAP kan resultere i stressbelastning på ligamentene til SI leddet når den samlede kraften overgår det som SI beltet totalt klarer å avlaste

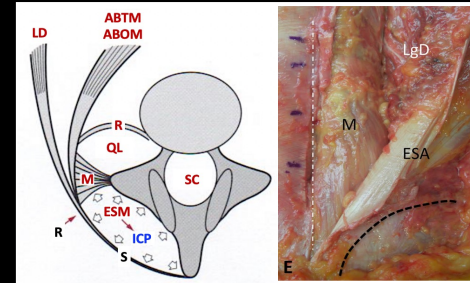


A Area of the mid-sagittal plane for the abdominopelvic cavity

a Area of the mid-sagittal plane of the pelvic cavity



Hydraulic Amplifier Effect



Økt Tensjon
FTL + AWT

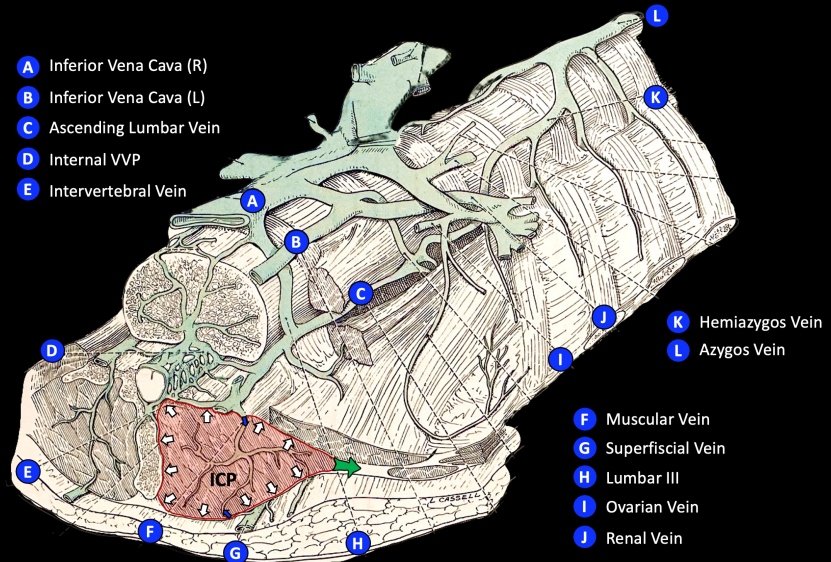
+

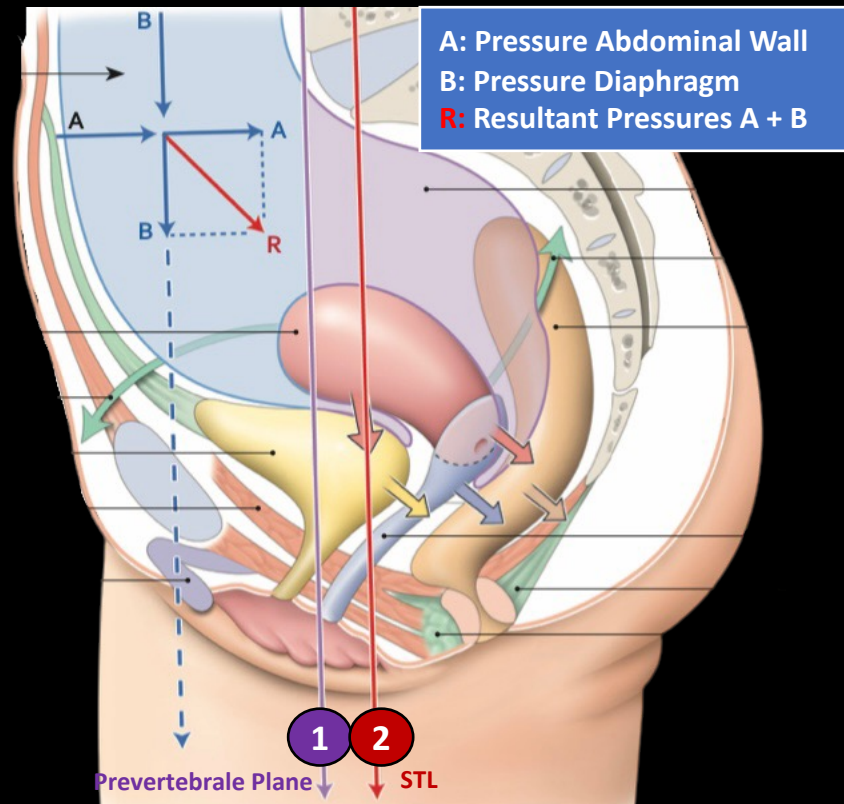
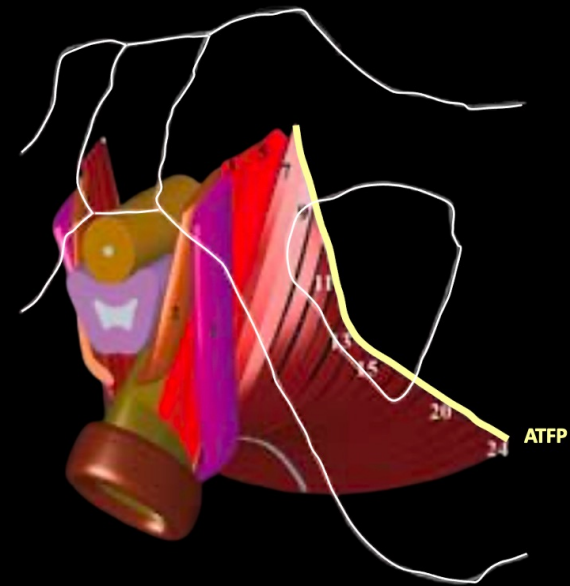
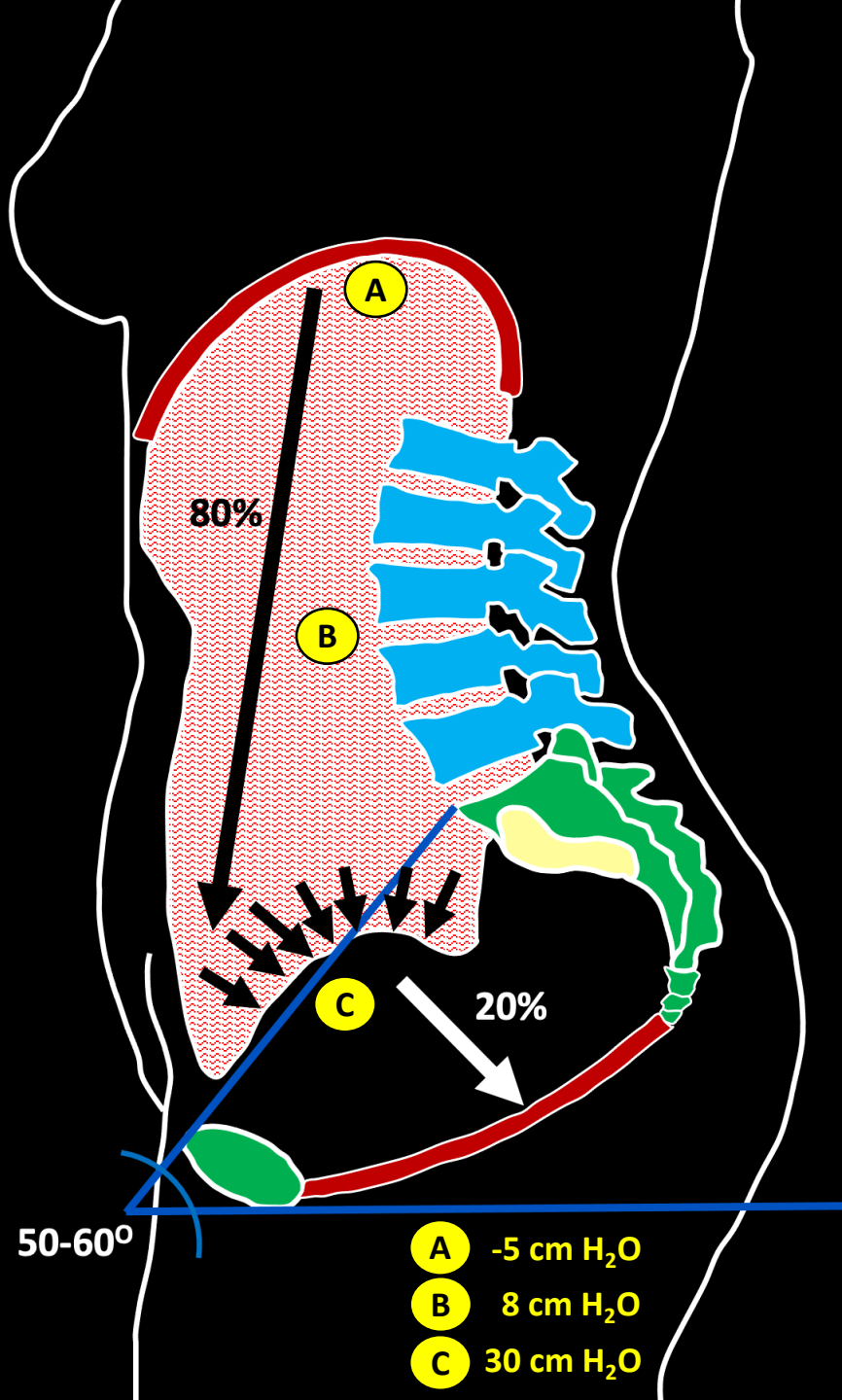
Økt Venøst
Trykk

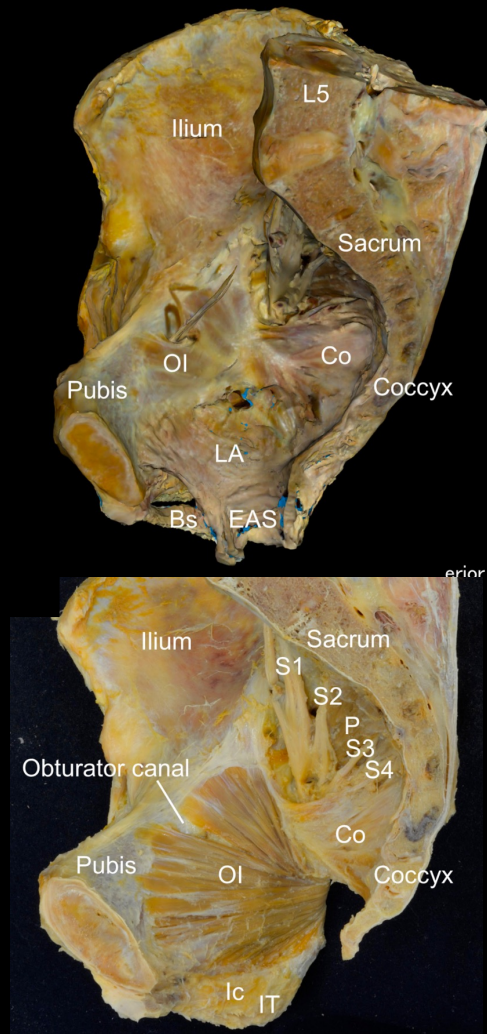
ICP
Økes

Stabilisering
Lumbosacrale
Kurve

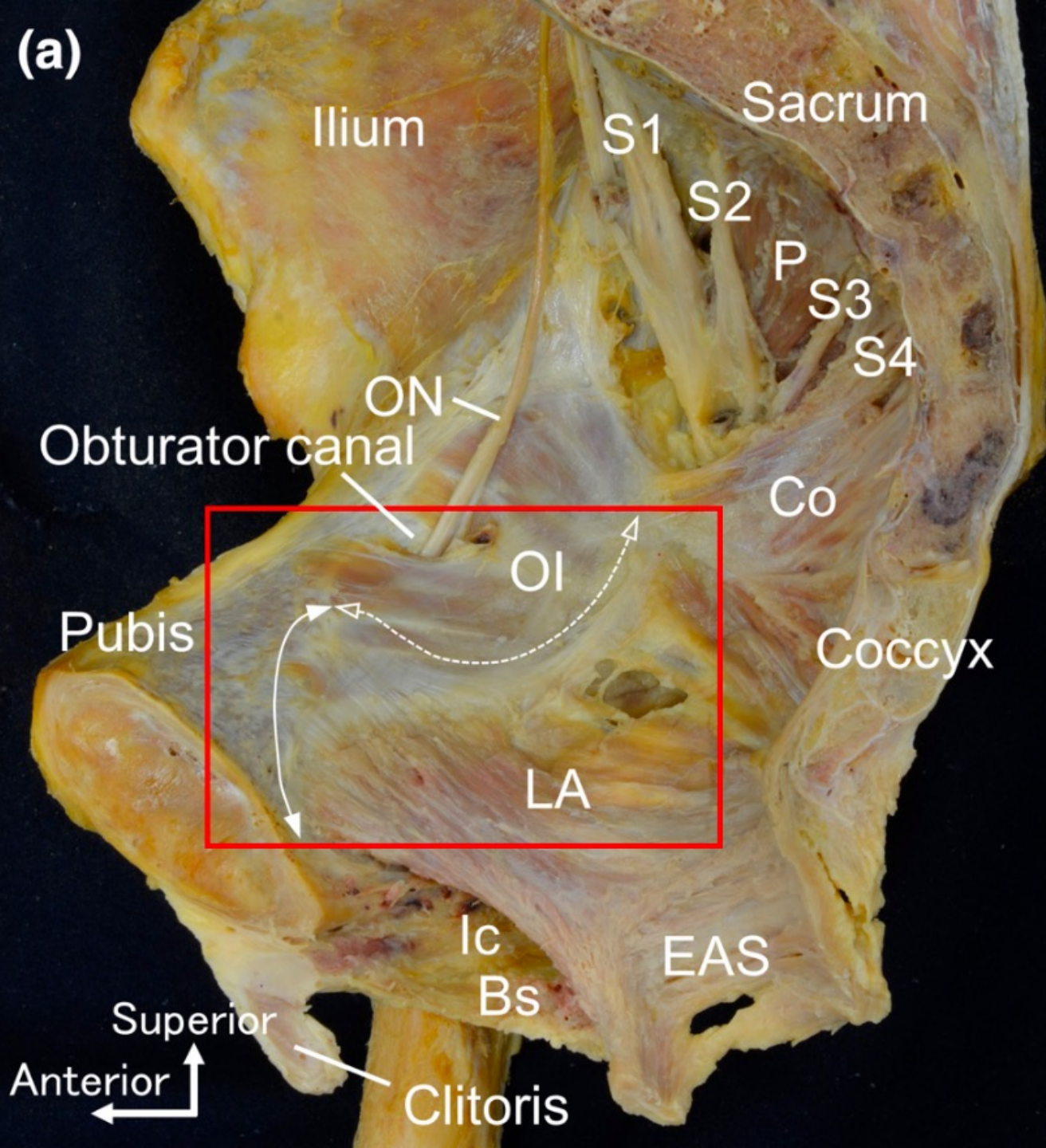
Normal Fordeling av IAP







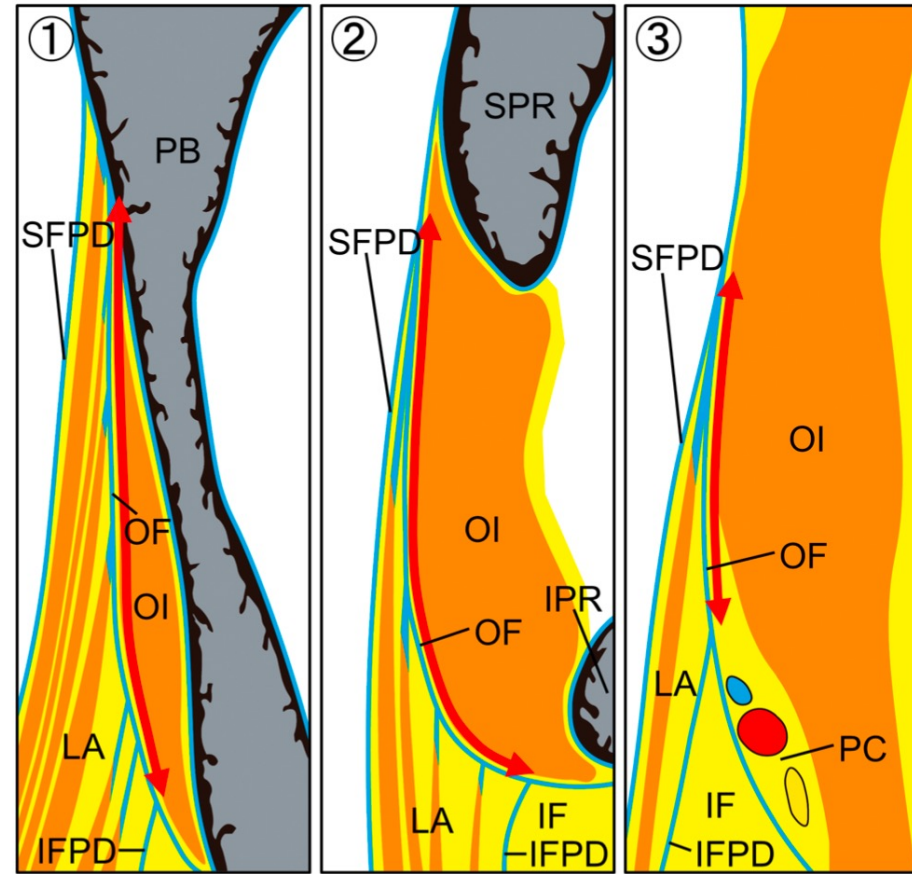
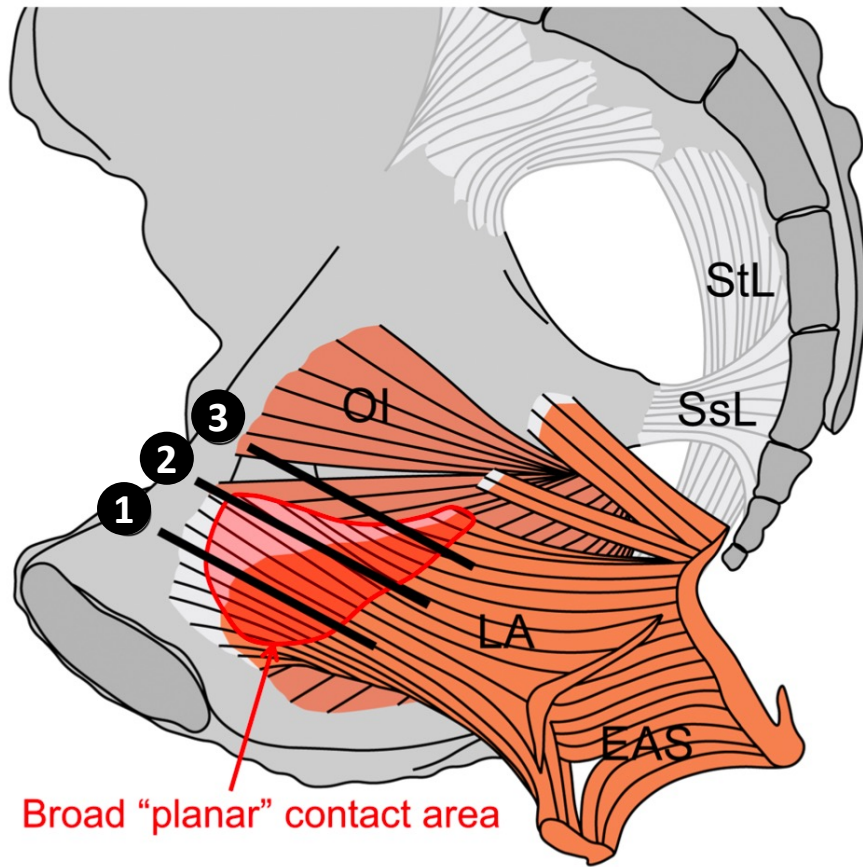
(a)



Chin HY et al. Attachment of the levator ani muscle extends to the superior ramus of the pubic bone through electrophysiological and anatomical examinations. *Scientific Reports* (2021) 11: 9483

Muro S et al. Anatomic basis for contribution of hip joint motion by the obturator internus to defaecation/urinary by the levator ani via obturator fascia. *Journal of Anatomy* (2022) 0: 1 - 9

Broad «planar» contact between the OI and LA



- ❶ Body of the pubis
 - ❷ Superior pubic ramus
 - ❸ Obturator canal
- EAS:** External anal sphincter
IF: Ischioanal Fossa

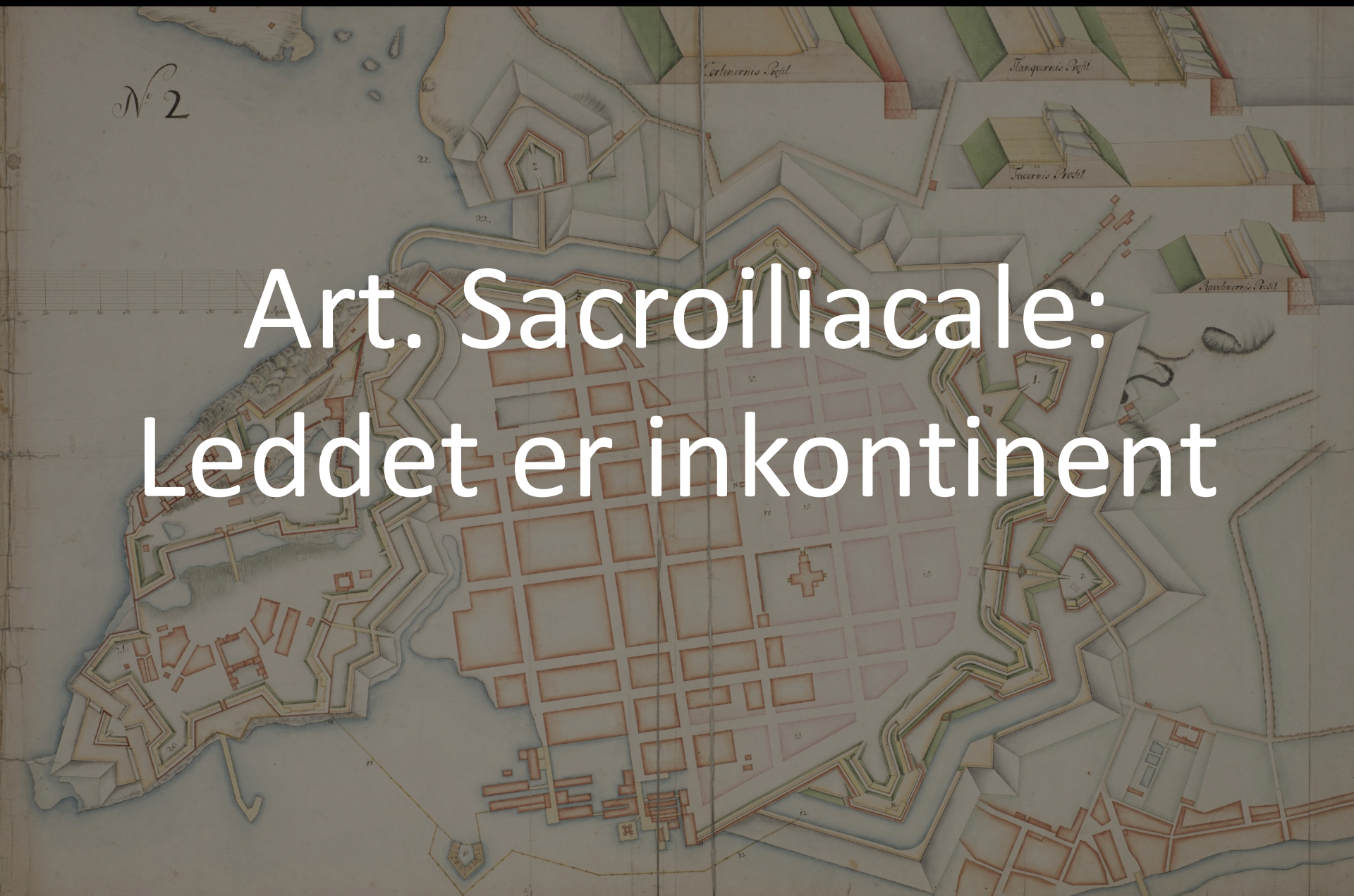LA: Levator ani
IFPD: Inferior Fascia Pelvic Diaphragm
OI: Obturator internus
SFPD: Superior Fascia Pelvic Diaphragm

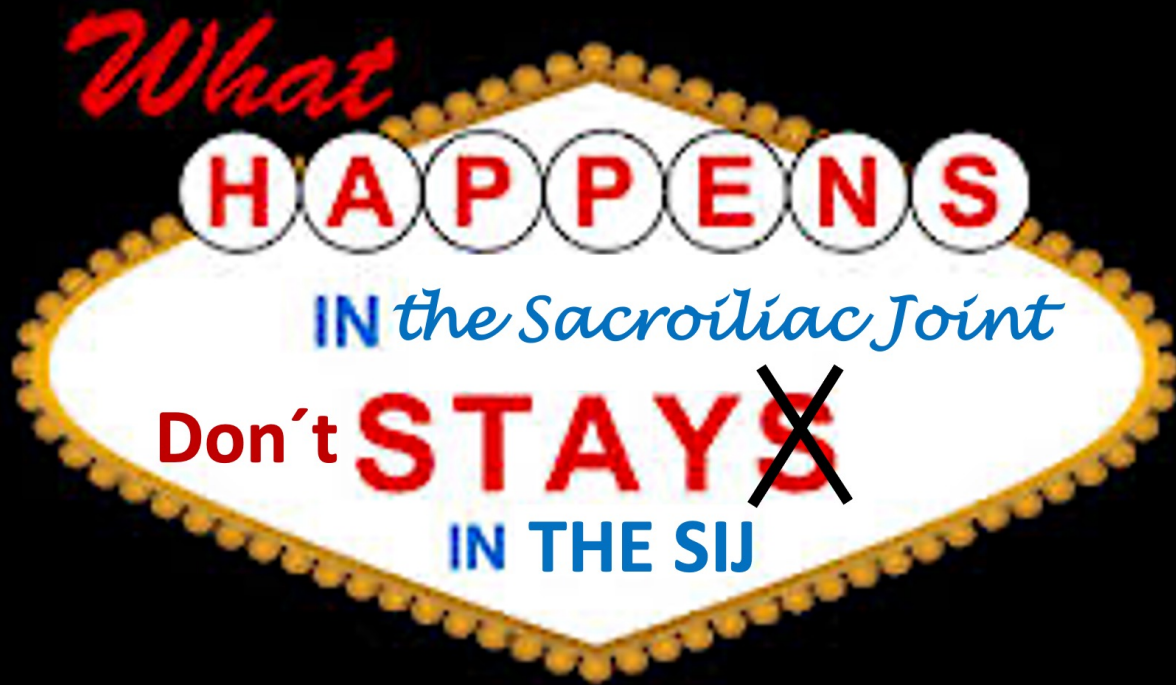IPR: Inferior pubic ramus
PB: Pubic body
PC: Pudendal canal
SPR: Superior pubic ramus

Muro S et al. Anatomic basis for contribution of hip joint motion by the obturator internus to defaecation/urinary by the levator ani via obturator fascia. *Journal of Anatomy* (2022) 0: 1 - 9

N^o 2

Art. Sacroiliacale:
Leddet er inkontinent



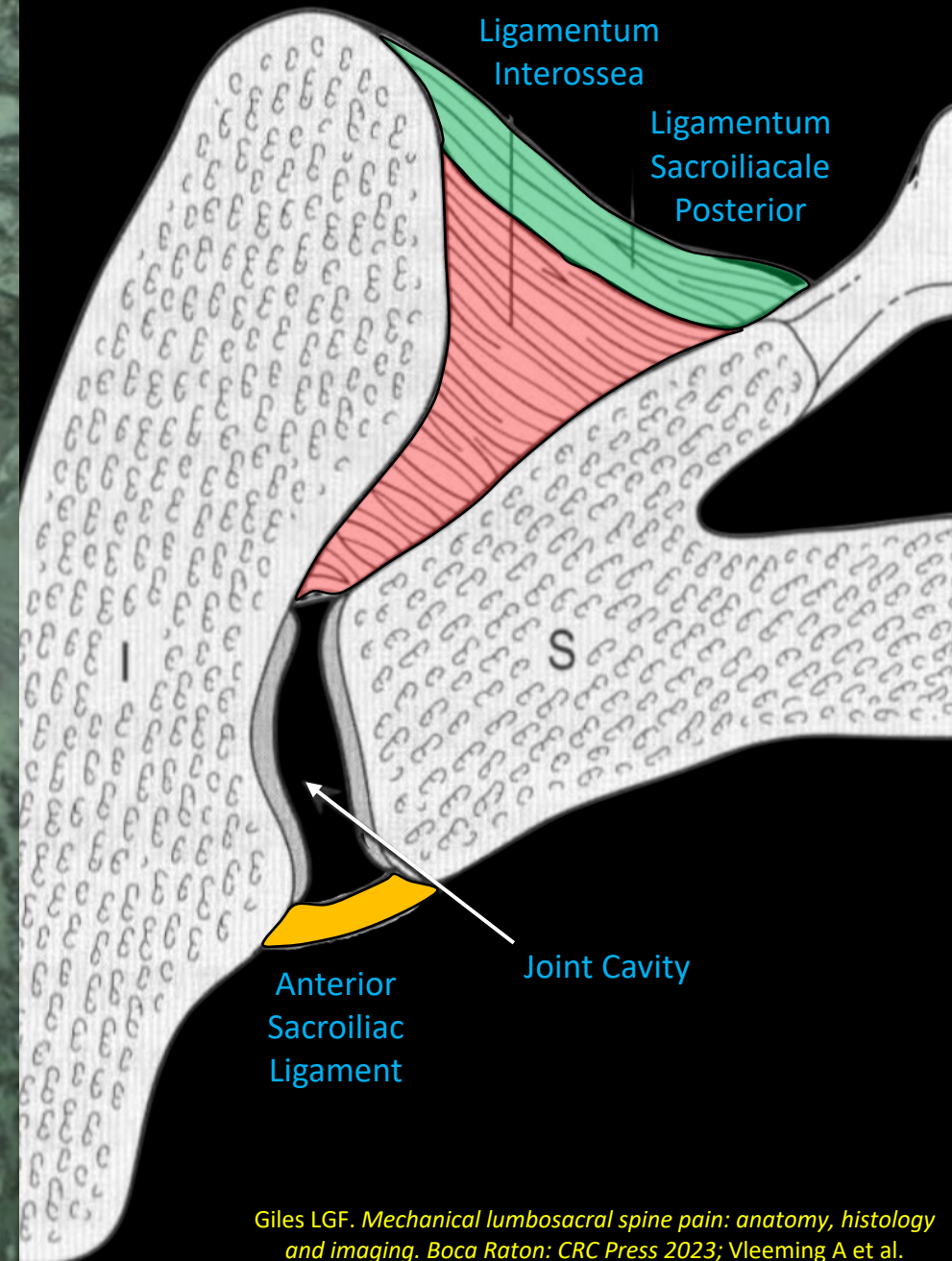
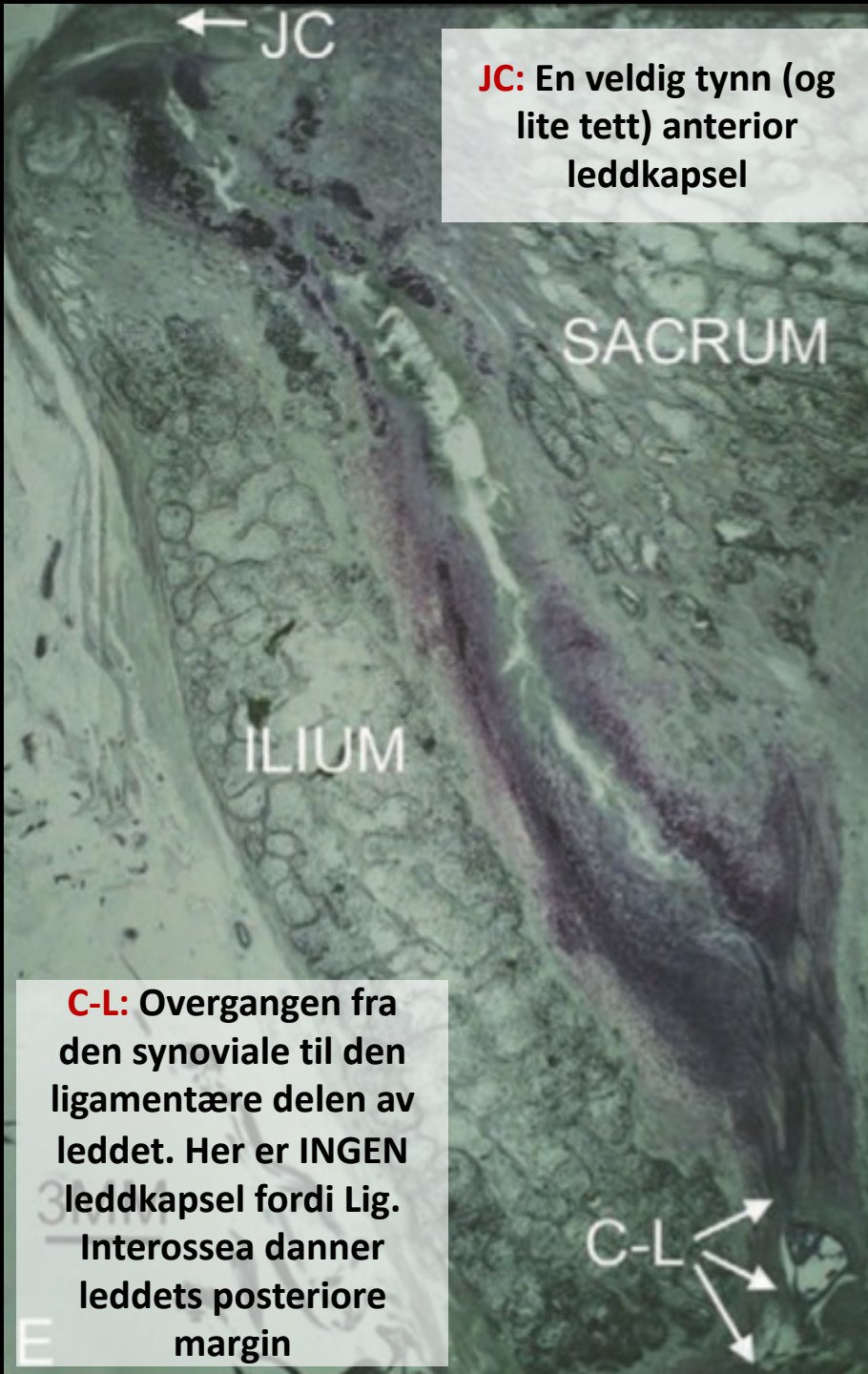

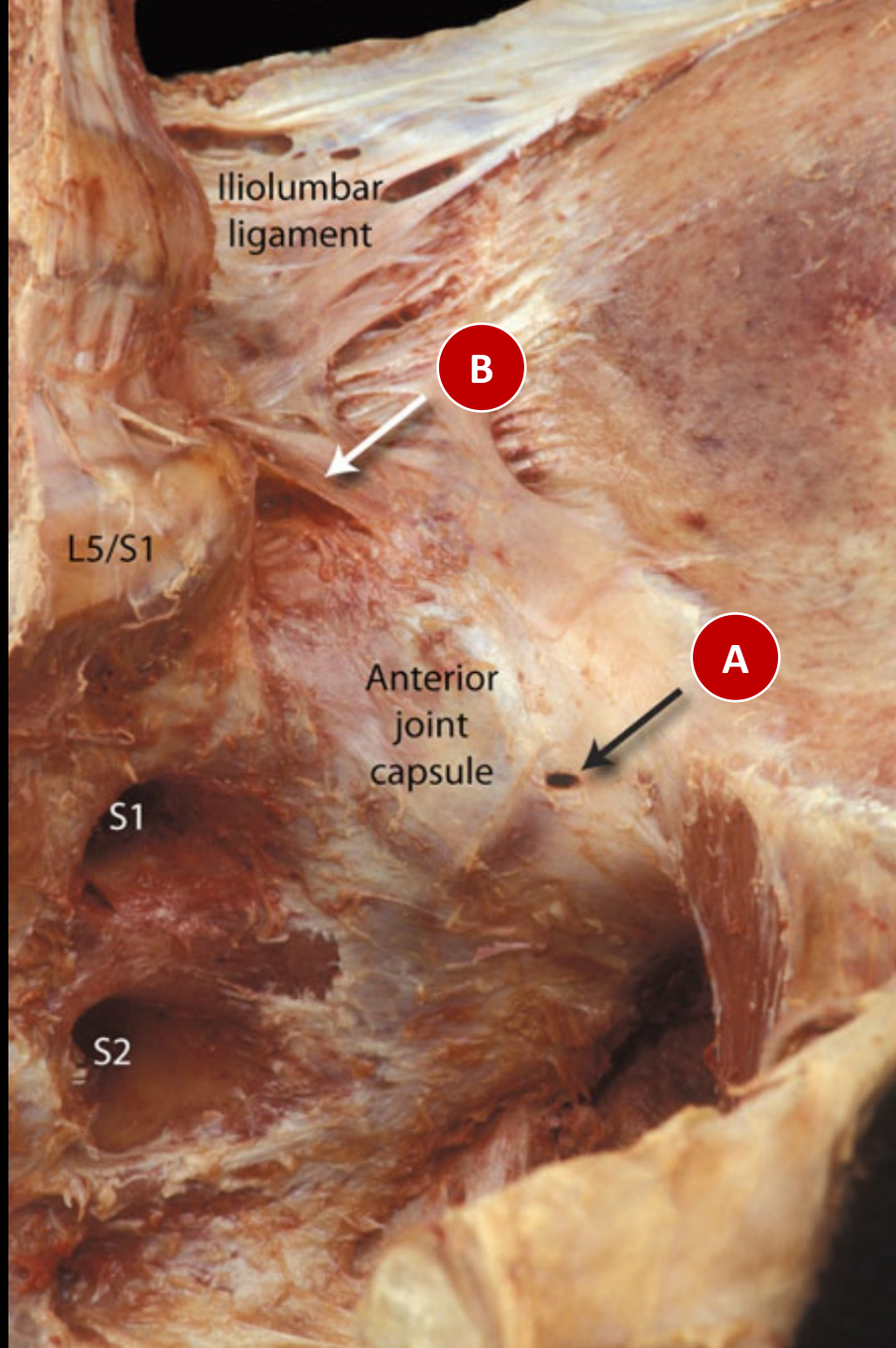
Self-Reported Female Orgasm Following Serial Sacroiliac Joint Injections

Nicholas R. Storlie ¹, Hamid Abbasi ^{2, 3}

1. Spine Surgery, Inspired Spine Health, Burnsville, USA 2. Neurosurgery, Ambulatory Surgical Clinic, Tristate Brain and Spine Institute, Alexandria, USA 3. Neurosurgery, Inspired Spine Health, Burnsville, USA

Storlie N R, Abbasi H (July 29, 2021) Self-Reported Female Orgasm Following Serial Sacroiliac Joint Injections. Cureus 13(7): e16737. DOI 10.7759/cureus.16737





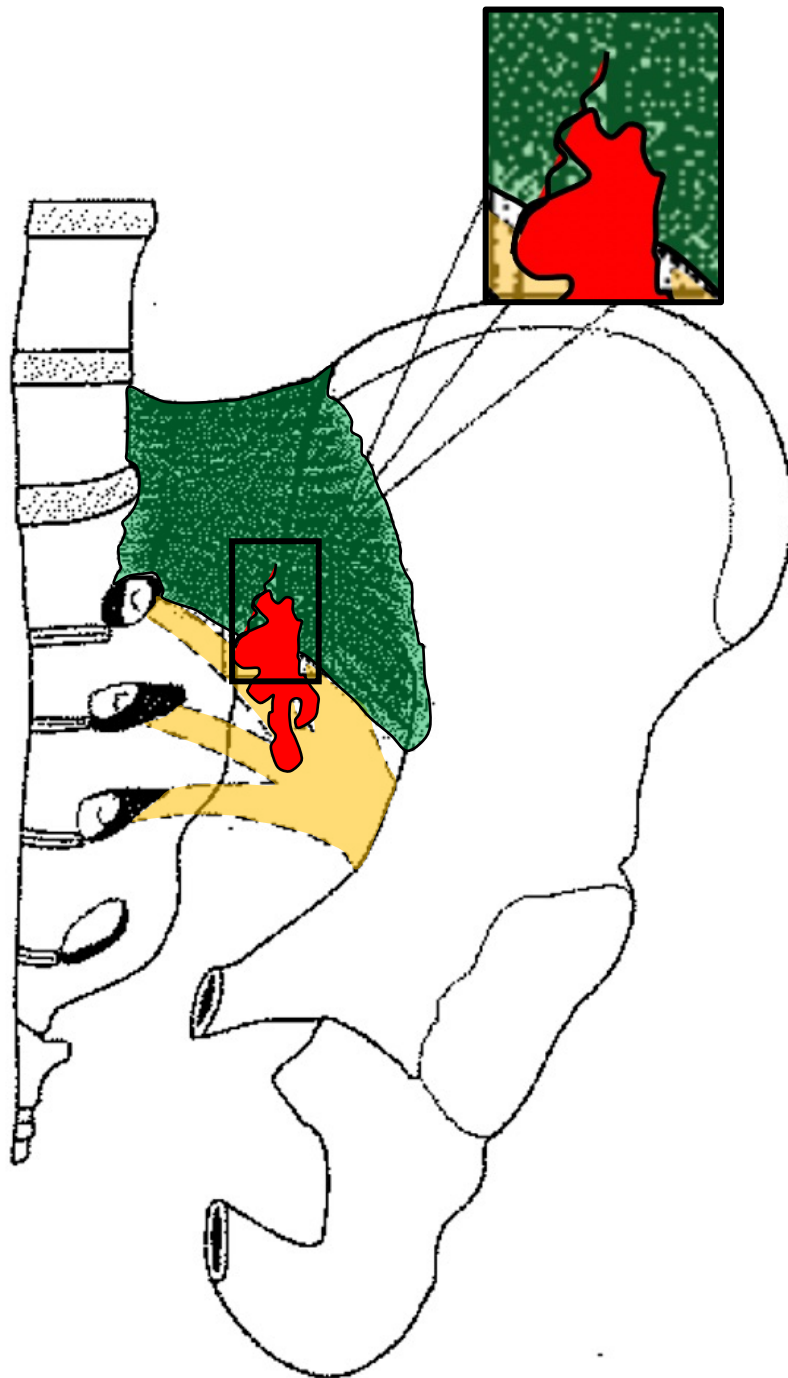
Willard FH, Schuenke MD. Neuroanatomy of female pelvic pain. In: Bailey A (ed): *Pain in Women*. Heidelberg: Springer 2013

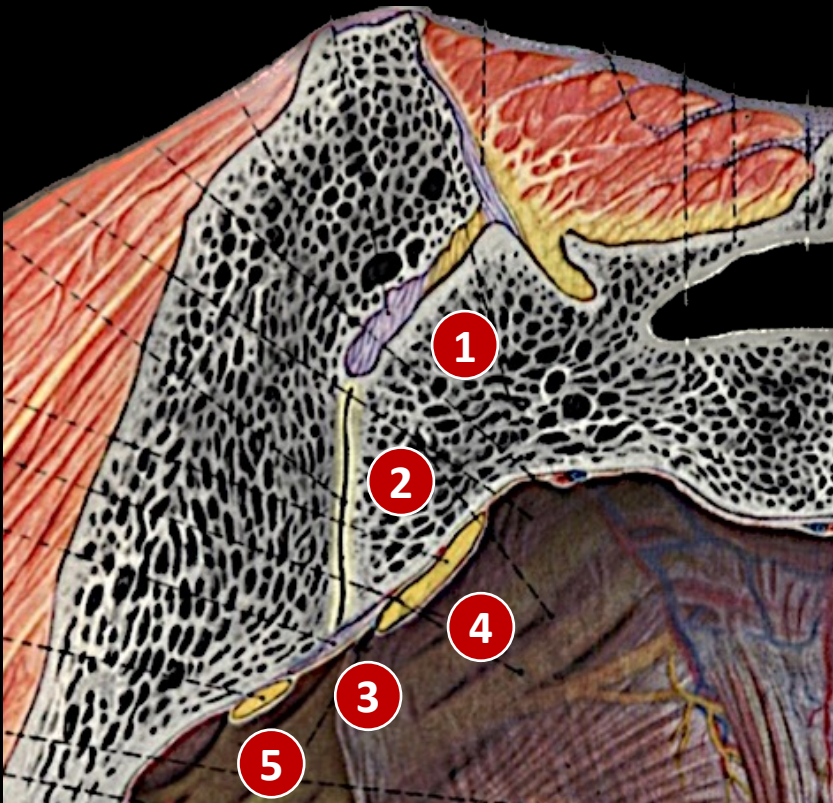
Forbindelse mellom SI Leddet og Nervale Strukturer

- Injeksjon kontrastvæske under fluoroskopi med artrografi i sacroiliacal leddet
- CT bilder for fremstilling av ekstravasasjonsmønstre av kontrastvæsken fra leddet
- Tre veier fra SI leddet til nervale strukturer
 - **Foramen Sacrale**
 - **Superior recessus i regionen til det epiradikulære rommet til rot L5**
 - **Plexus Lumbosacralis**

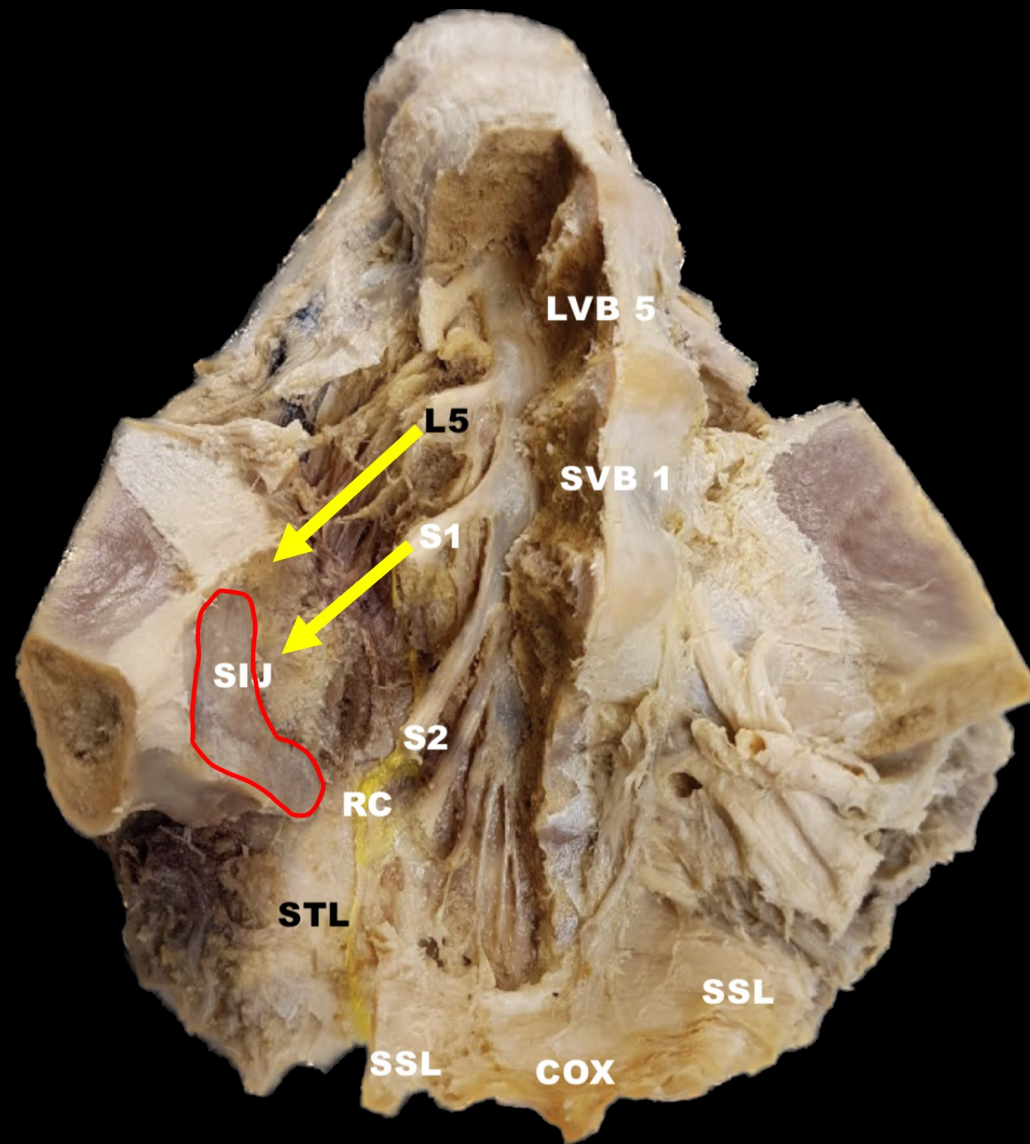
Fortin JD, Washington WJ, Falco FJE. Three pathways between the sacroiliac joint and neural structures. *AJNR Am J Neuroradiol.* 29: 1429-1434, 1999

Fortin JD, Vielnsky JA, Merkel GE. Can the sacroiliac joint cause sciatica? *Pain Physician* 6(3): 269 – 271, 2003

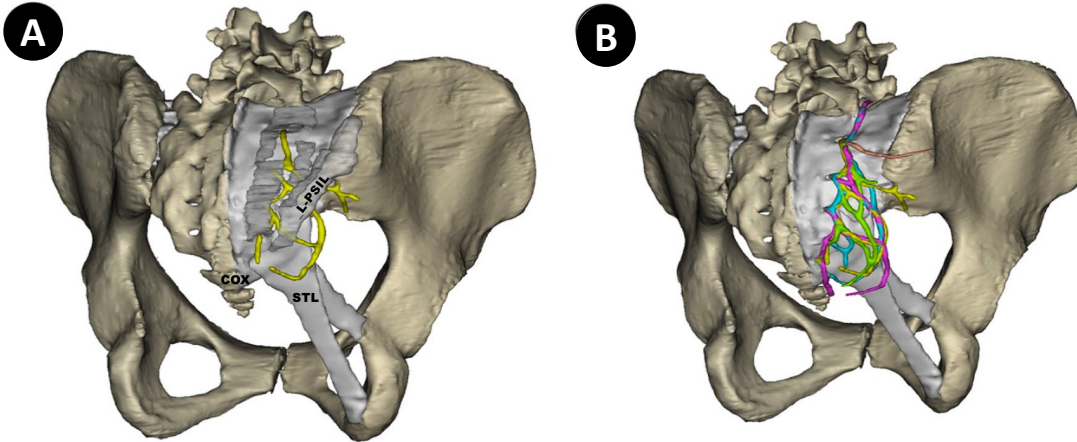




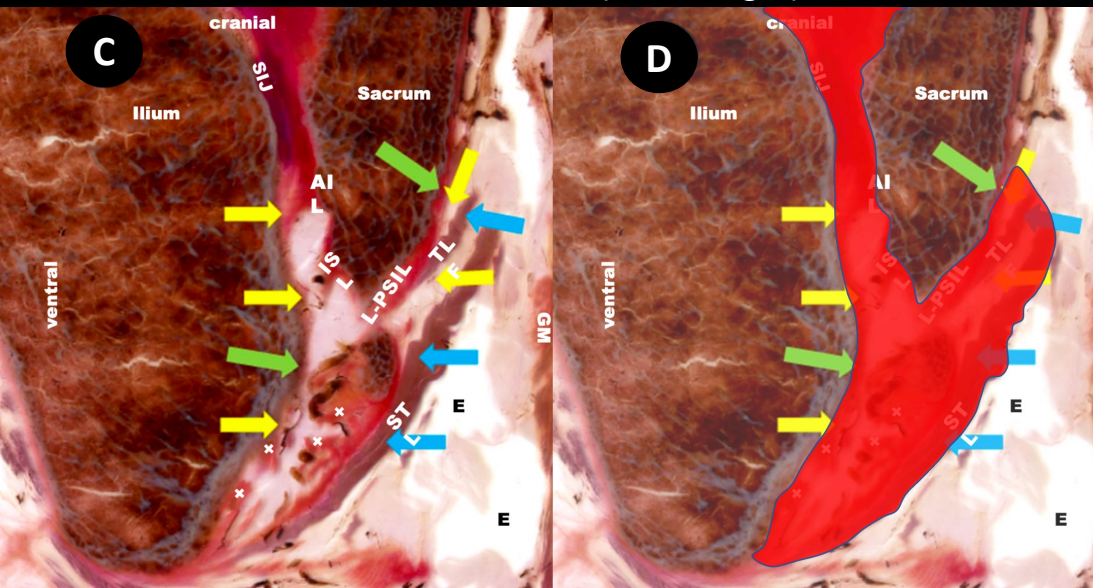
- ① Ligamentær Del SI - Leddet
- ② Artikulær Del SI - Leddet
- ③ Lig. Sacroiliacale Anterior
- ④ Ramus Ventralis S1
- ⑤ Ramus Ventralis L5



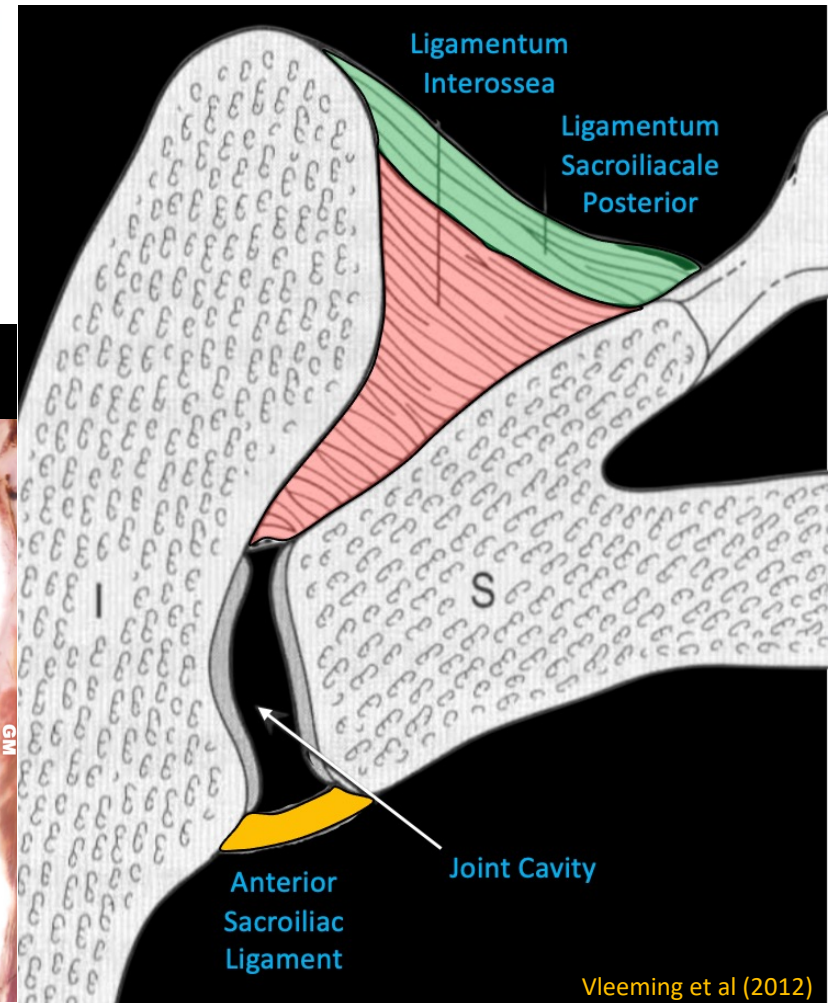
Steinke H et al. Sacroiliac innervation.
European Spine Journal 27 August 2022



Ekstravasasjon av veske fra SIL til de posteriore ligamentære og fascielle strukturer (bilde C og D)



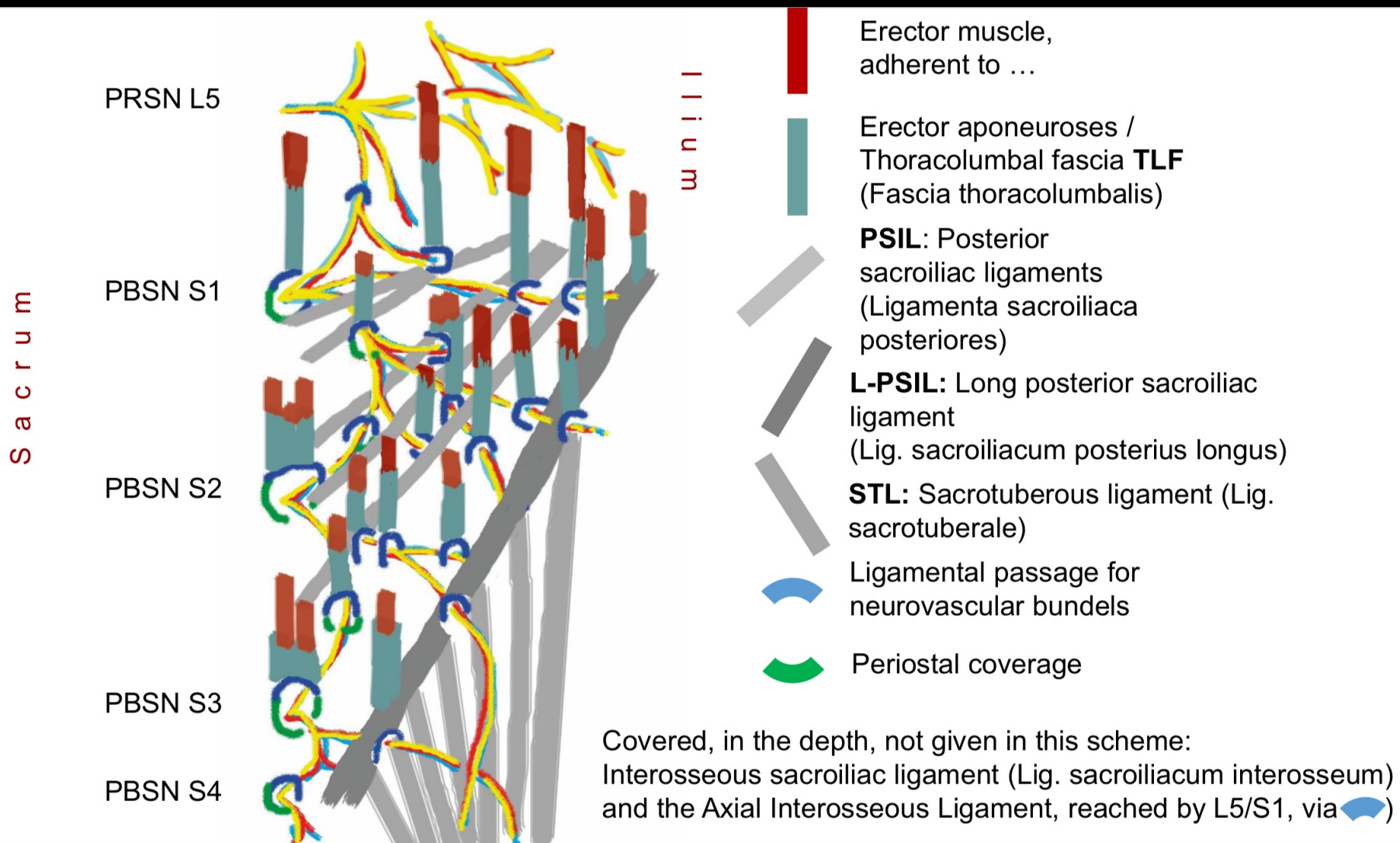
Steinke H et al. Sacroiliac innervation.
European Spine Journal 27 August 2022



Vleeming et al (2012)

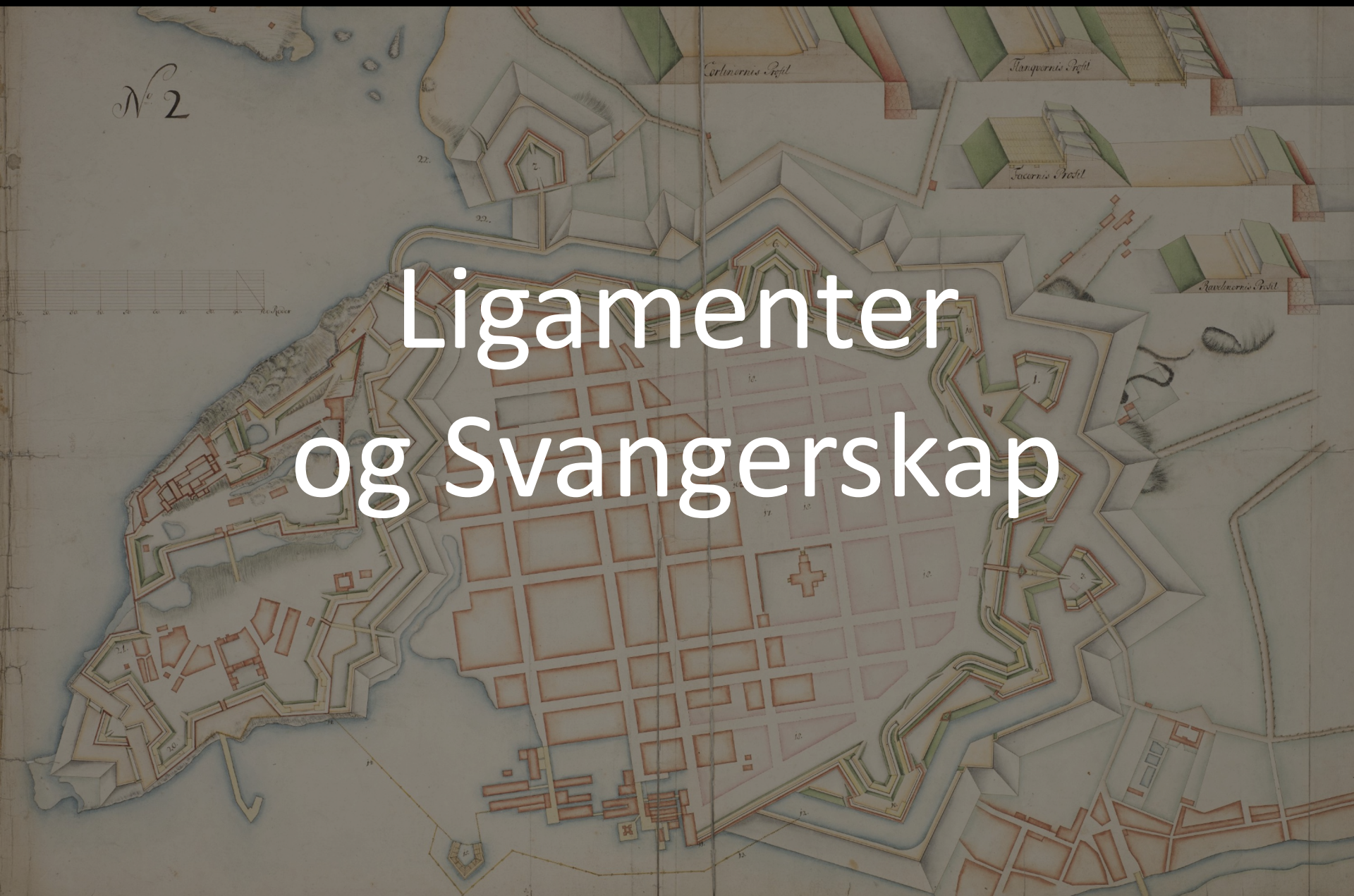PBSN: Posteriore Grene Nn. Sacrales

RC L5/S1	RC S1/S2	RC S2/S3	RCS3/S4	RCS4/S5	RC S5/Cocc
Passerer Lig. Iliolumbale og Lig. Interossea	Inferior for SIPS Ventral for LSIP-L Loop til STL	Medial for LSIP-L Loop til STL Nivå L5 til Cocc.	Ventral for LSIP-L	Krysser med mangfoldige RC forgreninger	Forløper langsmed Coccygeus

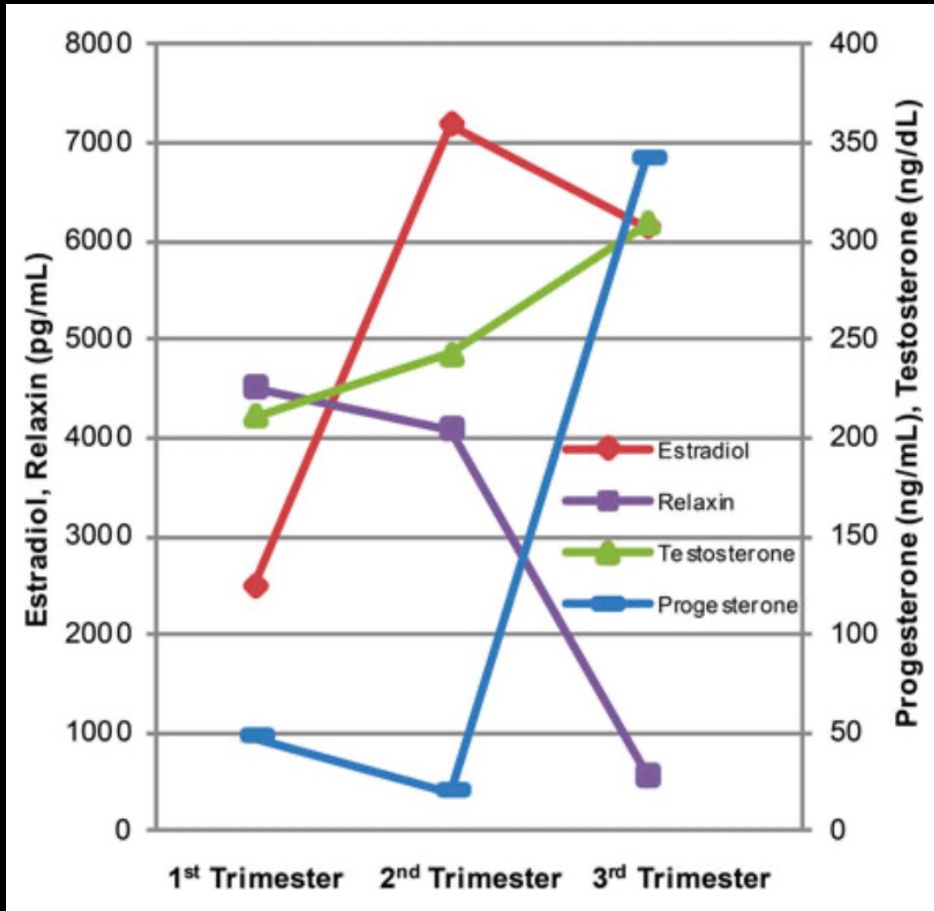


N^o 2

Ligamenter og Svangerskap



Hormonelle Endringer Svangerskap



Store individuelle variasjoner: øverste serum-nivå representert i grafene

Abbassi-Ghanavati, Mina; Greer, Laura; Cunningham, F. *Obstetrics & Gynecology*. 114(6):1326-1331, December 2009; Vollestaad *Man Ther* 2012; Karger 1998; Kristiansson *AJ OB Gyn* 1996

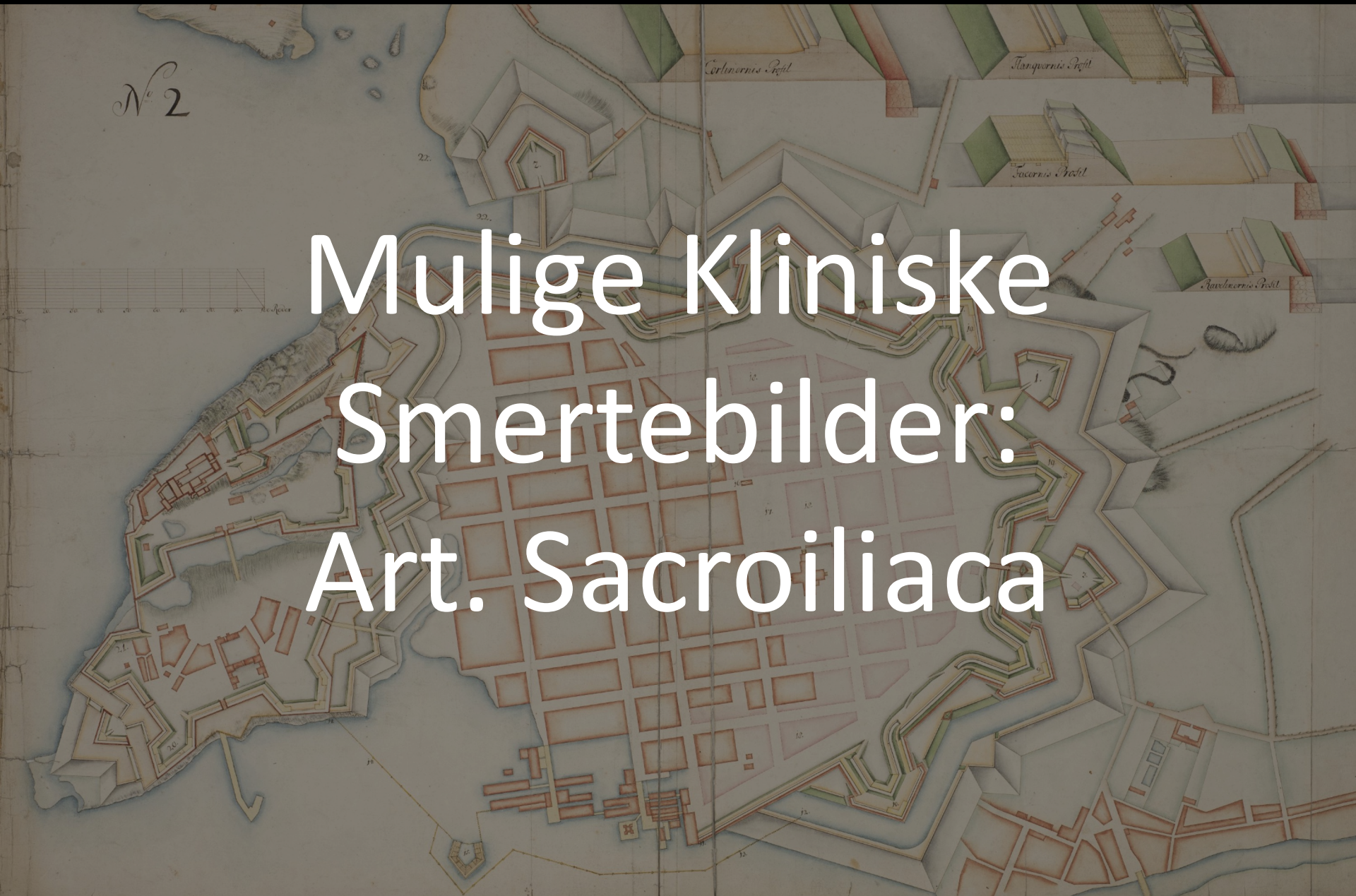- Til tross for at kvinner går gjennom en rekke hormonelle endringer under svangerskap er korrelasjonen mellom hormonene og utvikling av PGP og LBP fortsatt uklar¹
- Asymmetri i ligamentær laksitet er viktigere en graden av laksitet for SI ledd smerter²

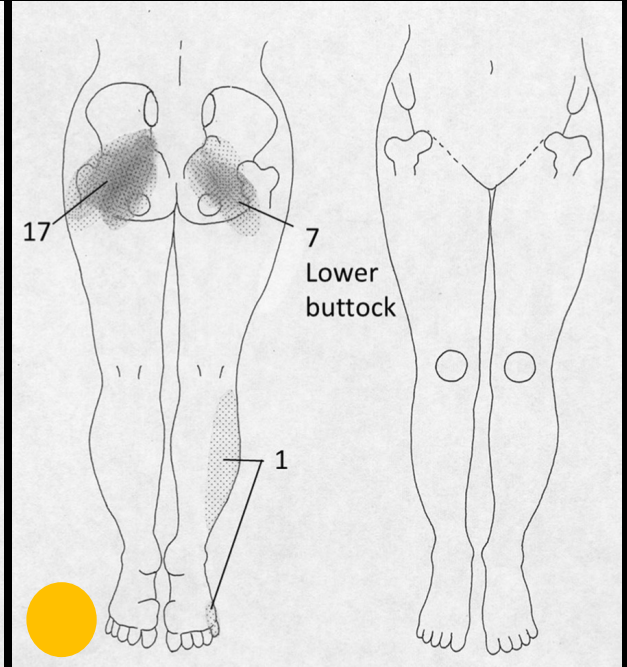
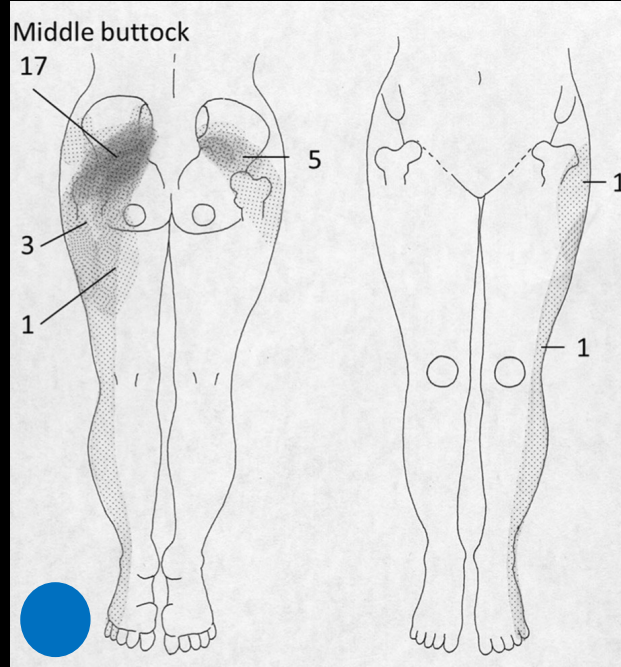
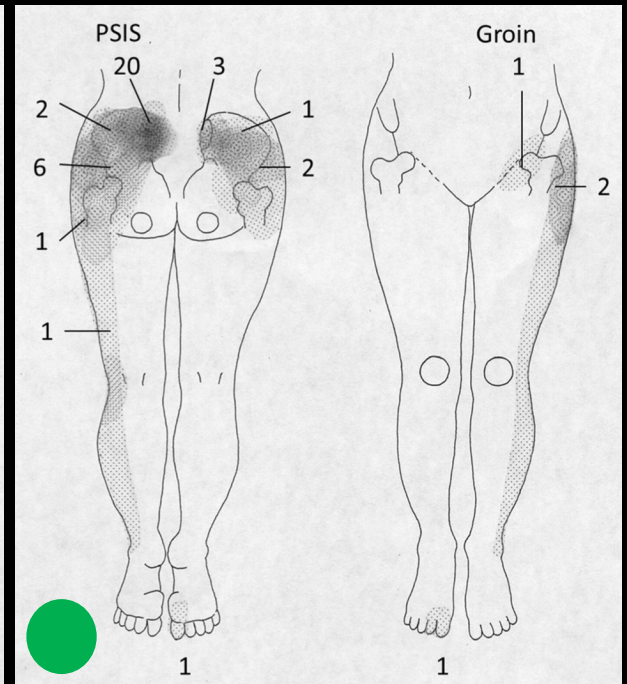
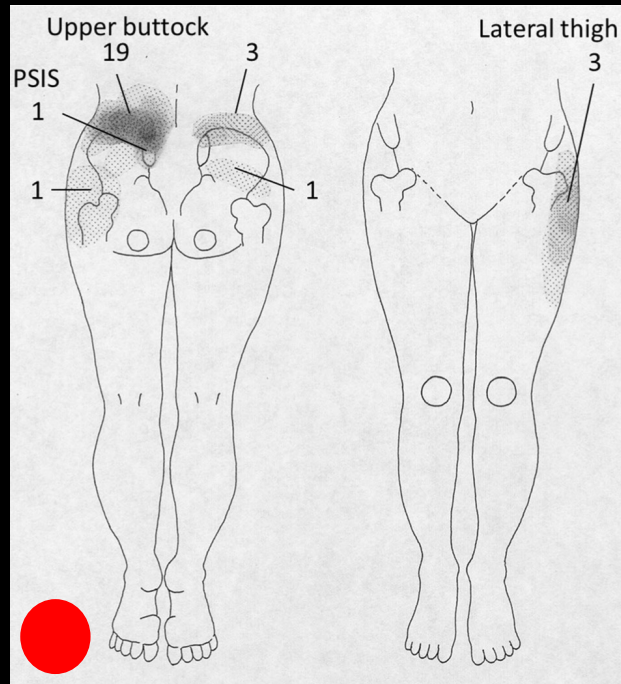
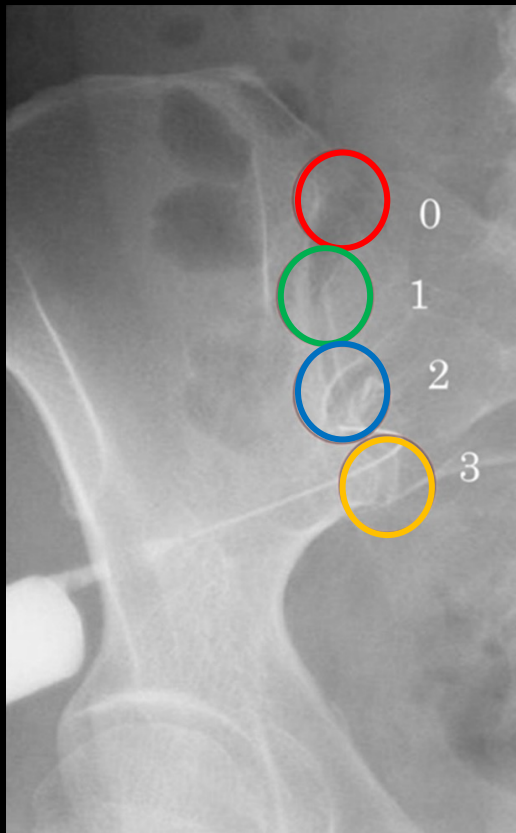
¹Daneau C et al. Association between pregnancy-related hormones and lumbopelvic pain characteristics in pregnant women: a scoping review. *J Manipulative Physiol Ther* 2021; 44: 573-583

²Enix DE, Mayer JM. Sacroiliac joint hypermobility biomechanics and what it means for health care providers and patients. *PM R* 11(2019) S32-S39

N^o 2

Mulige Kliniske Smertebilder: Art. Sacroiliaca





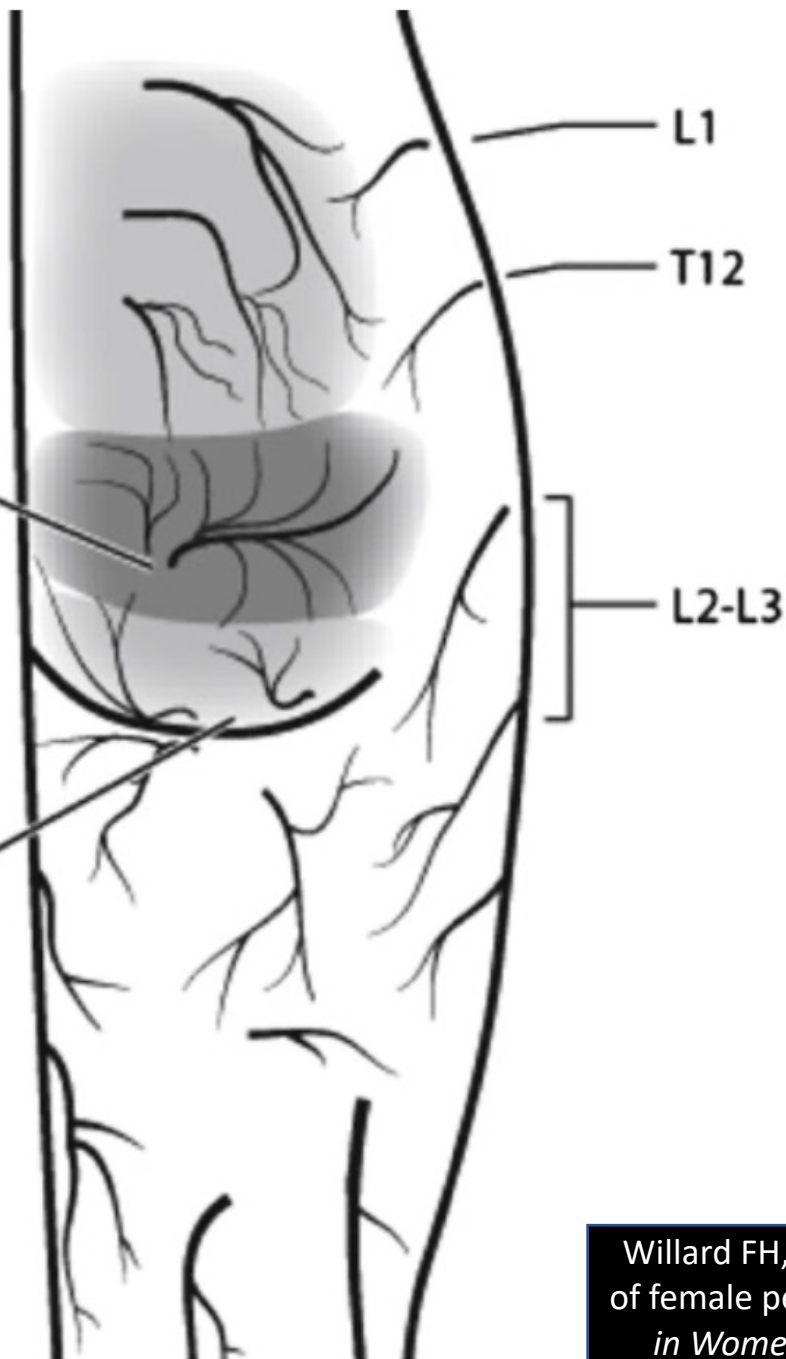
Bemerkning: Alle fire seksjonene kunne forårsake lyskesmerter når de ble stimulert

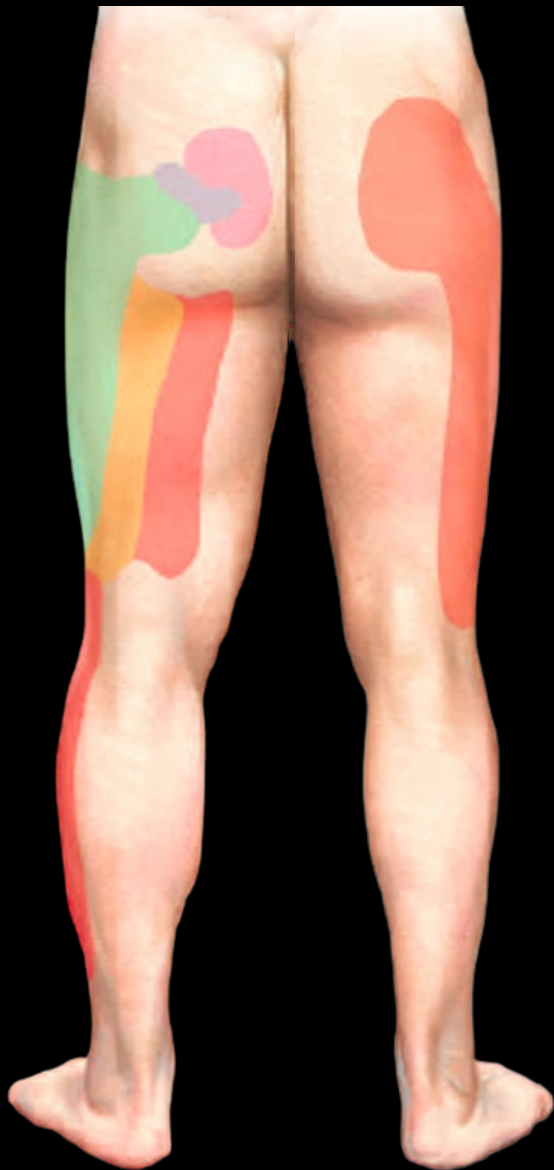Kurosawa D et al. Referred pain location depends on the affected section of the sacroiliac joint. *Eur J Spine* (2015) 24: 521-527

L1-L3 Dorsal
lumbar rami
(Superior cluneal
nerves)

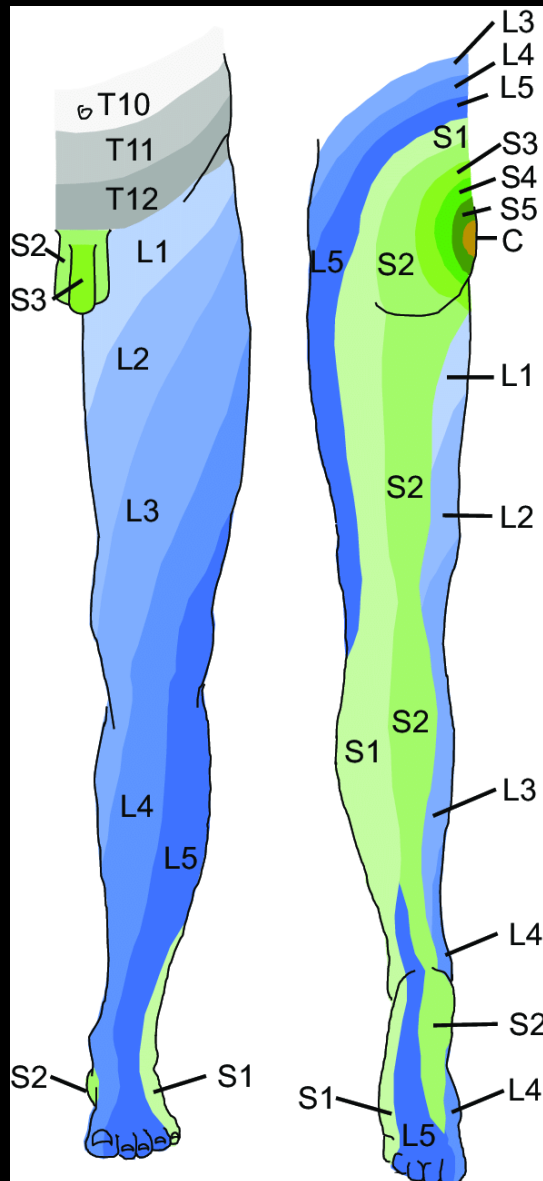
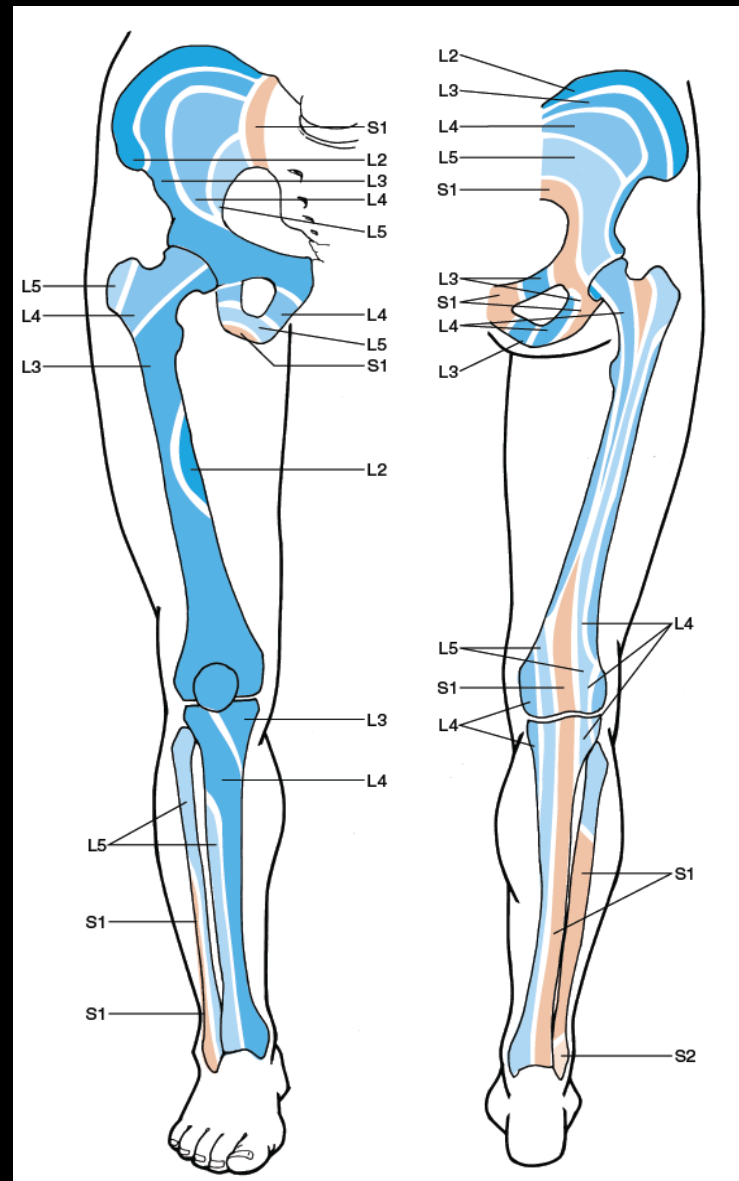
S1-S3 Dorsal
sacral rami
(Middle cluneal
nerves)

S1-S3 Posterior
cutaneous nerve of the
thigh
(Inferior cluneal
nerves)



A«Klassiske Smerte-
mønstre» fra SI-Ledd**B**

«Isjiasdistribusjon»

**C**
Sklerotomer
 (noen bruker begrepet
 «Osteotomer»)


Kort om Sklerotomer

- Dette begrepet ble brukt for første gang i klinisk sammenheng i 1944 av Inman og Saunders, og refererte til smertedistribusjon i den segmentelle innervasjonen av knokler
- Det embryologiske paraksiale mesodermet (som er viktig for segmentering av kroppen) har både en dermatomyotomal del og en sklerotomal del, og dette ansees som opphavet for denne distribusjonen
- Smerte i sklerotomal distribusjon kan oppleves spesielt fra cervical column, lumbal column og bekkenregionen, inklusiv SI – leddene
- En nyere studie fra Sverige (Torstensson et al, 2015) viste til at kvinner med kroniske bekkensmerter ofte hadde symptomer som samsvarte med sklerotom distribusjonene slik først beskrevet av Inman og Saunders (1944)

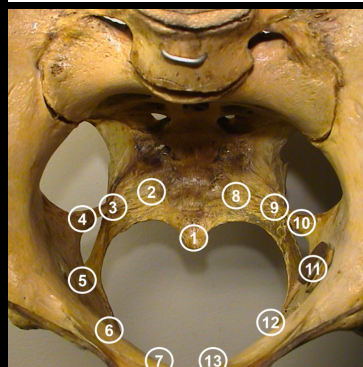
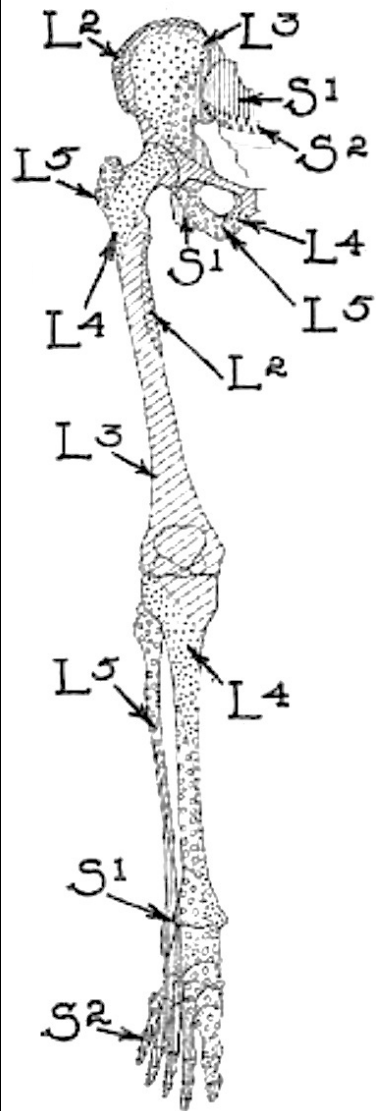
Referred Pain Patterns Provoked on Intra-Pelvic Structures among Women with and without Chronic Pelvic Pain: A Descriptive Study

Thomas Torstensson^{1,2☉*}, Stephen Butler^{1,3‡}, Anne Lindgren^{1,2☉}, Magnus Peterson^{1,3‡}, Margaretha Eriksson^{1‡}, Per Kristiansson^{1☉}

1 Department of Public Health and Caring Sciences, Uppsala University, Uppsala, Sweden, **2** Department of Physiotherapy, Sundsvall Hospital, Sundsvall, Sweden, **3** Pain Center, Uppsala University Hospital, Uppsala, Sweden

Conclusions

Referred pain patterns provoked from intra-pelvic landmarks in women with CPP are consistent with sclerotomal sensory innervation. Magnification of referred pain patterns indicates allodynia and central sensitization. The results suggest that pain mapping can be used to evaluate and confirm the pain experience among women with CPP and contribute to diagnosis.



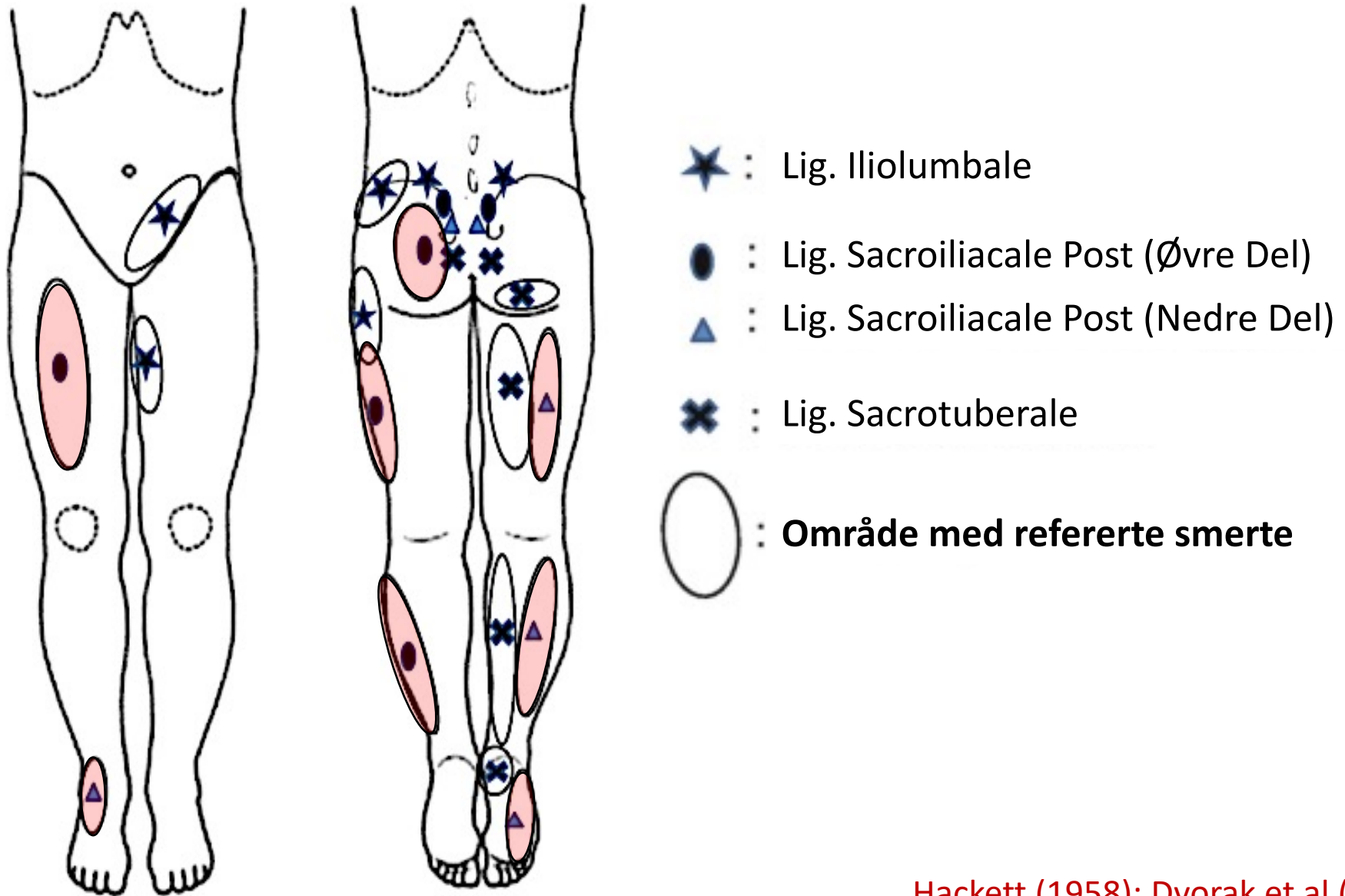
Inman VT, Saunders JB.
Referred pain from
skeletal structures. *J.
Nerv. Ment. Dis.*(1944);
99:660-667

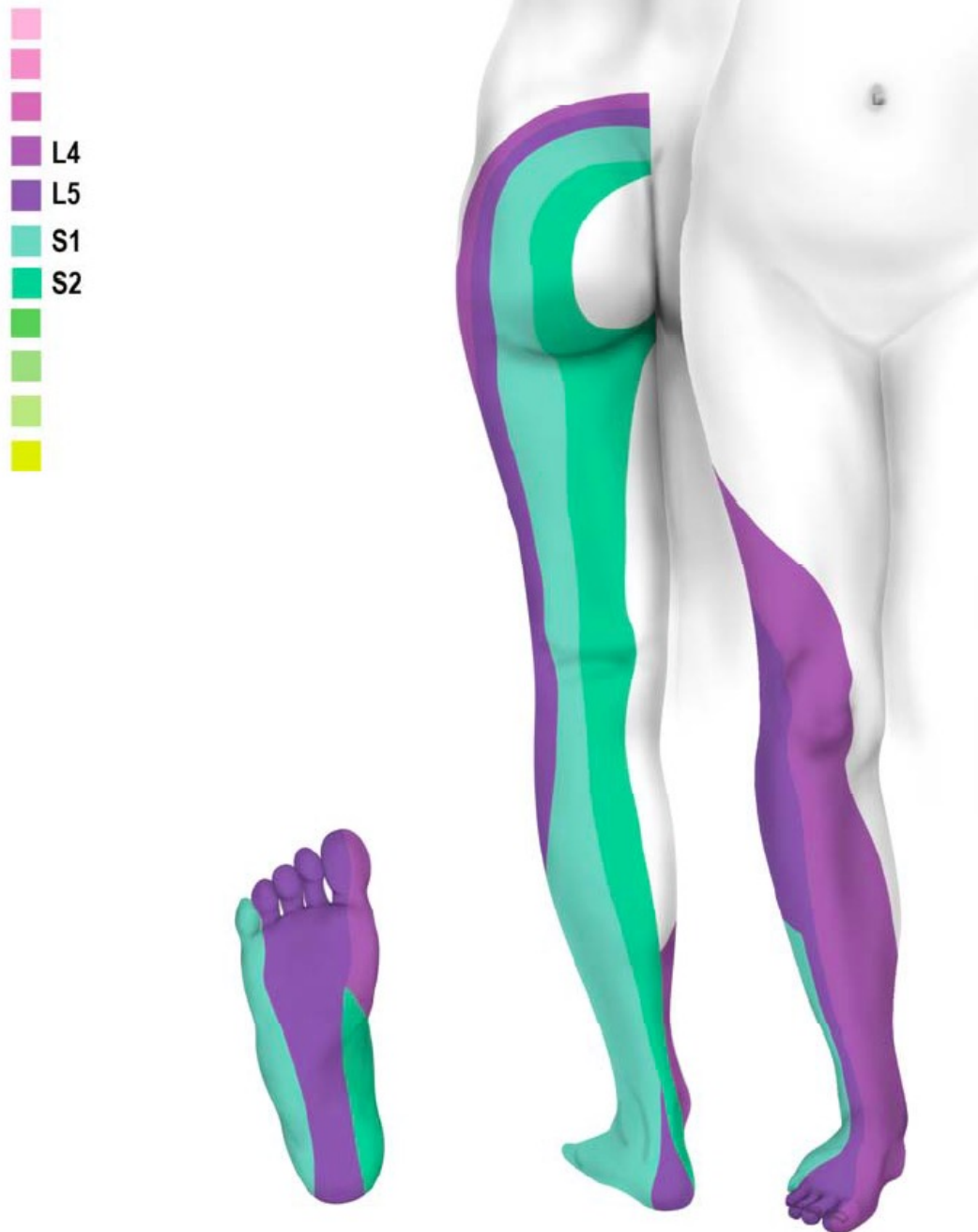
Citation: Torstensson T, Butler S, Lindgren A, Peterson M, Eriksson M, Kristiansson P (2015) Referred Pain Patterns Provoked on Intra-Pelvic Structures among Women with and without Chronic Pelvic Pain: A Descriptive Study. *PLoS ONE* 10(3): e0119542. doi:10.1371/journal.pone.0119542

Som kliniker eller terapeut tenker jeg det kan være nyttig å ha sklerotom-smerter i bakholdet når vi prøver å forstå pasientens beskrivelse av smerteopplevelsen. ***Og som dere ser, det kan være overlappende smertemekanismer fra SI – leddet:***

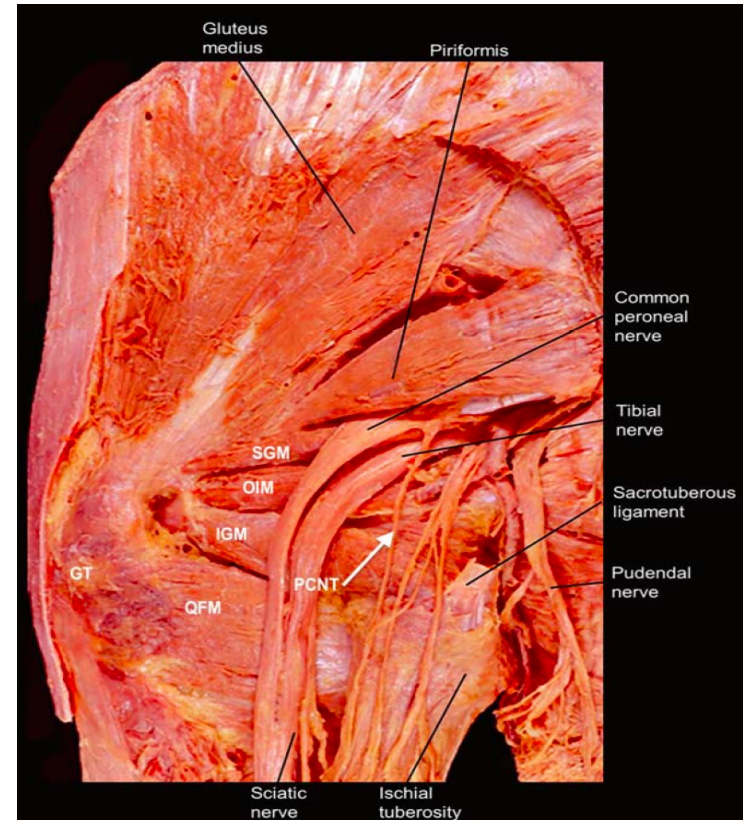
- «Klassiske smerter» med bakgrunn i SI-leddets anteriore og posteriore innervasjon
- Sensitivisering av nerver med topografisk nærhet til leddet grunnet «lekkasje»: L5 og S1 («isjias»); N. Obturatorius; N. Pudendus
- Nn. Clunei Mediale og Nn. Clunei Superiore
- Sklerotomdistribusjon

Ligamentære Smertemønstre





Dermatomes of the Sciatic Nerve



Boezaart AP. *The anatomical foundations of regional anesthesia and acute pain medicine*. UAE: Bentham Scientific Publishers 2016

Posterior femoral cutaneous



Common peroneal nerve

Deep peroneal nerve

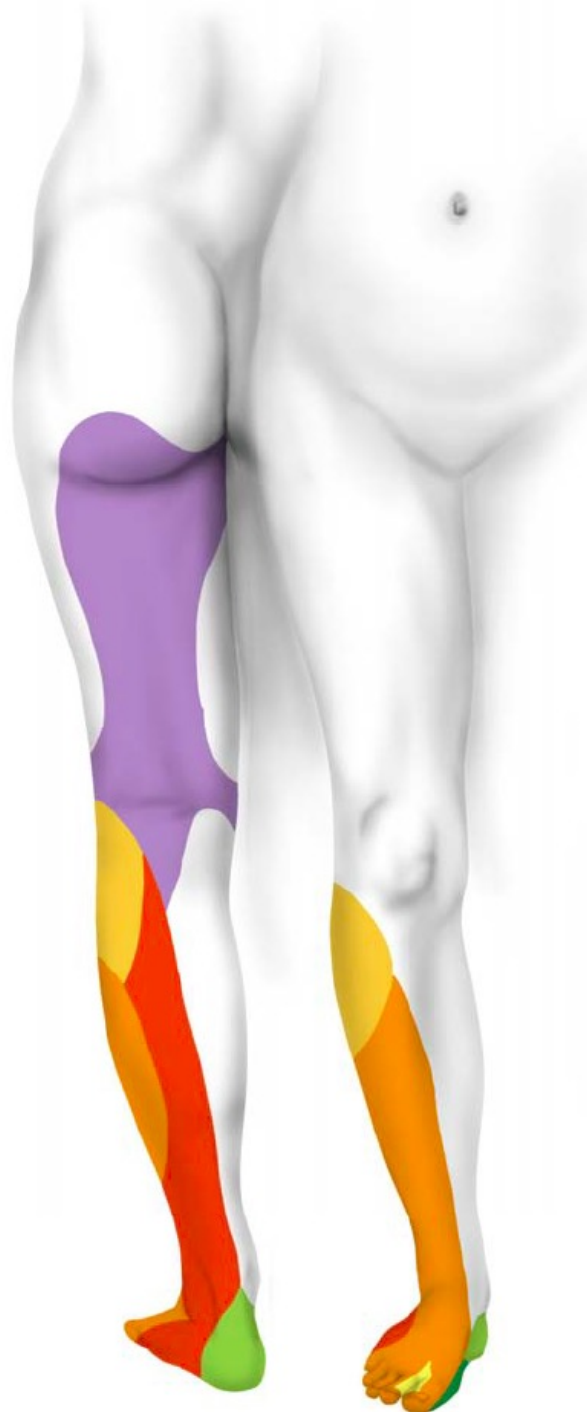
Superficial peroneal nerve

Sural nerve

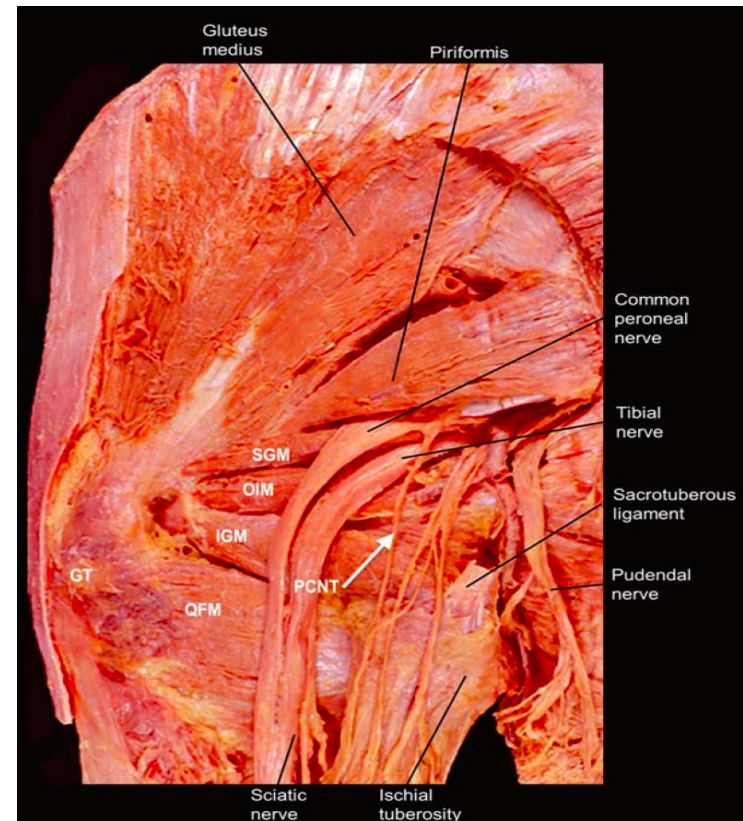
Lateral plantar nerve

Calcaneal nerve

Medial plantar nerve



Neurotome of the Sciatic Nerve



Boezaart AP. *The anatomical foundations of regional anesthesia and acute pain medicine*. UAE: Bentham Scientific Publishers 2016

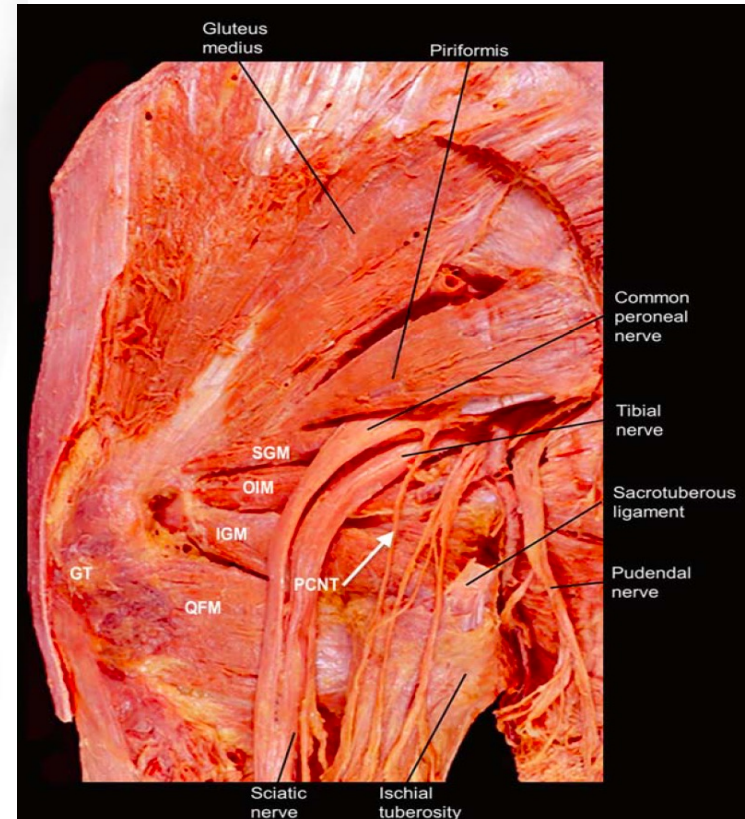
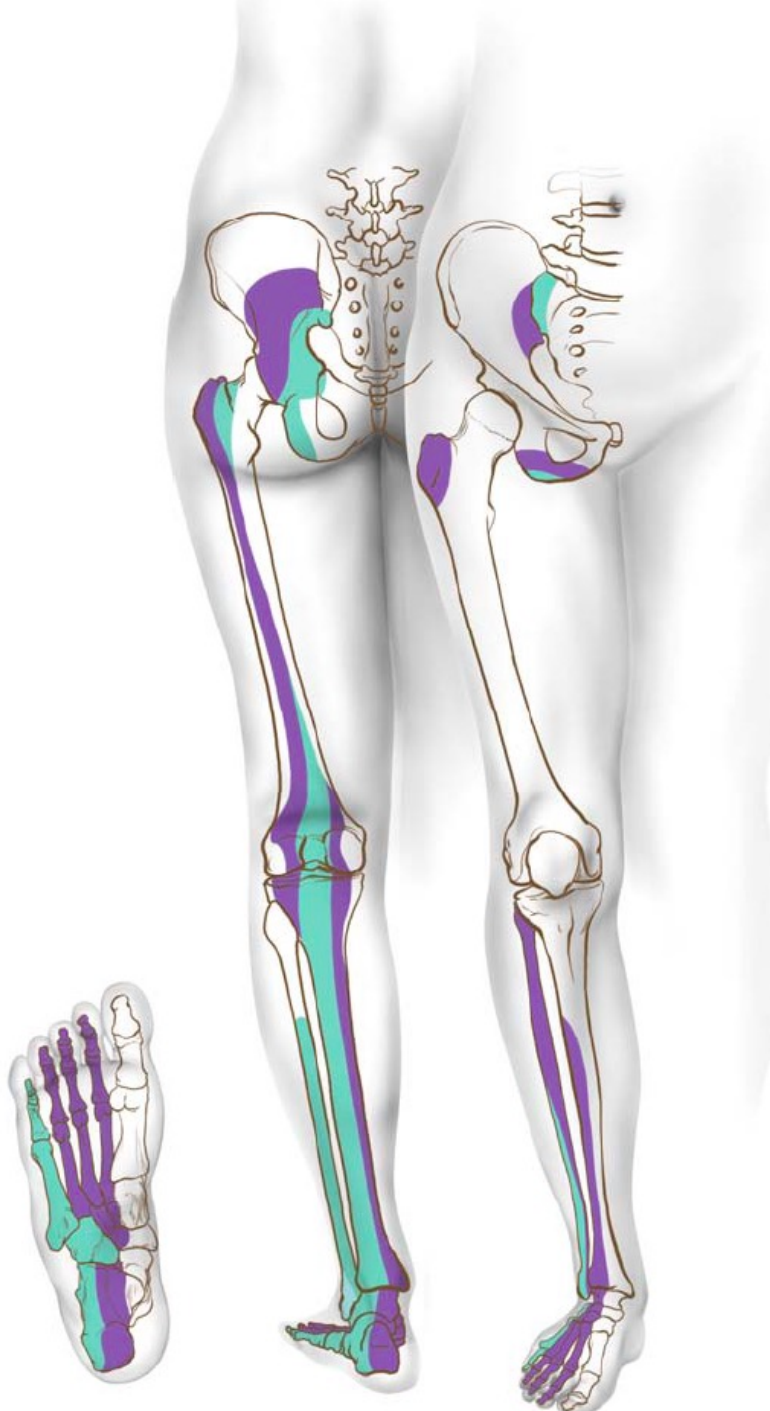Osteotomes of the Sciatic Nerve



L5

S1

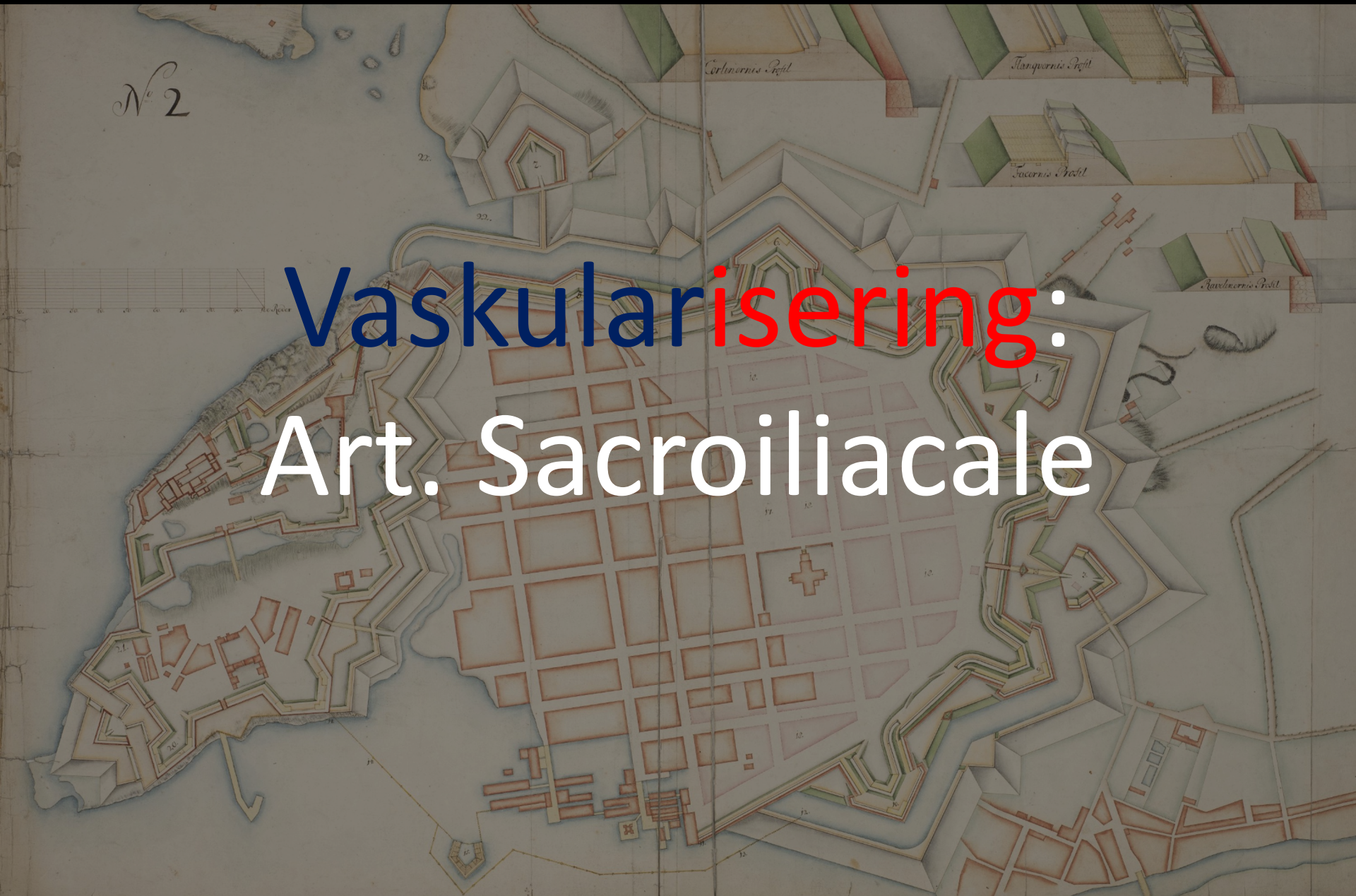S2



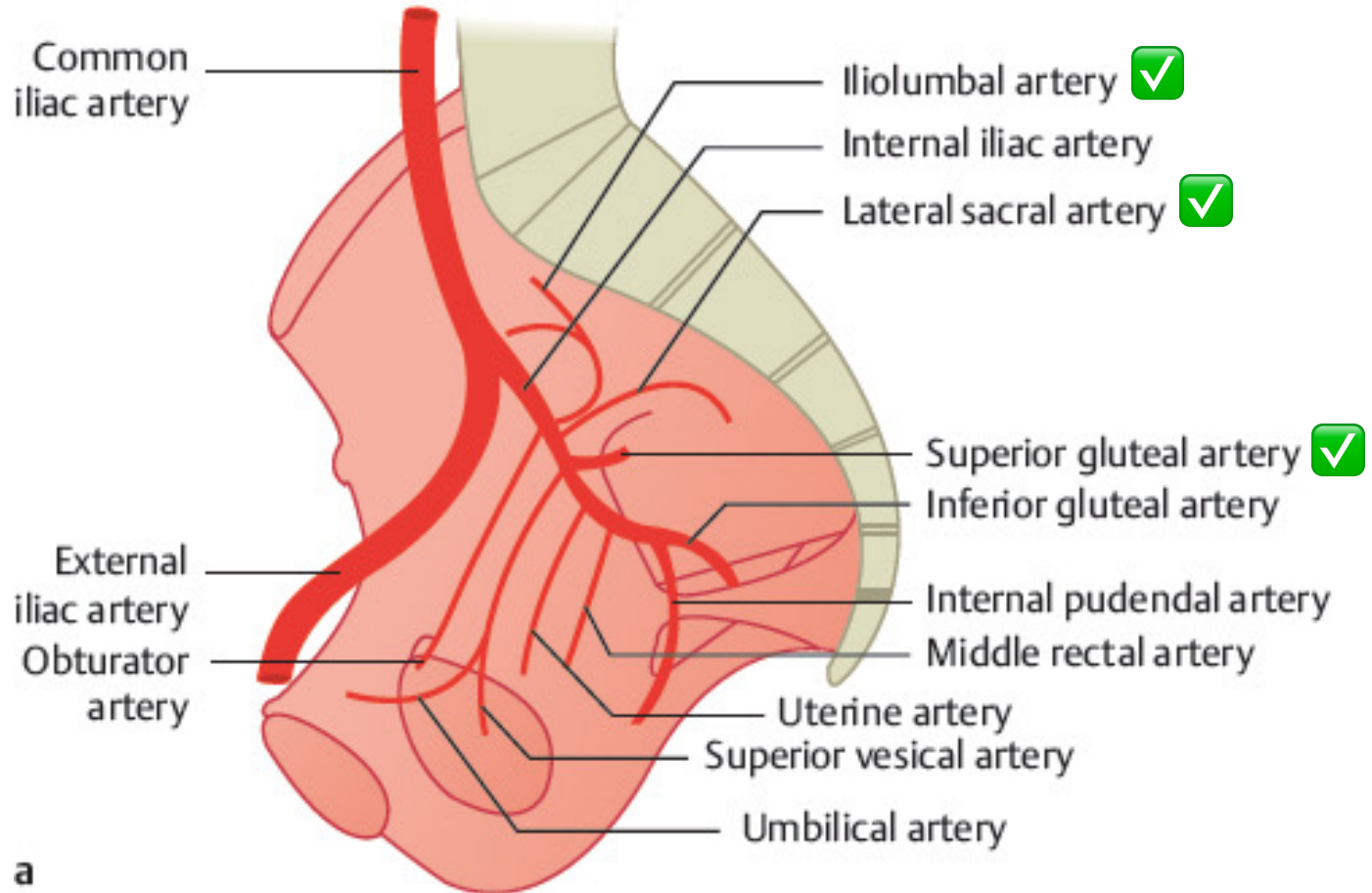
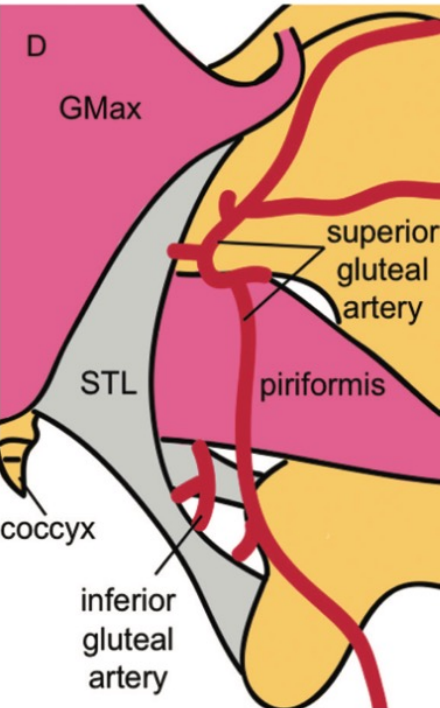
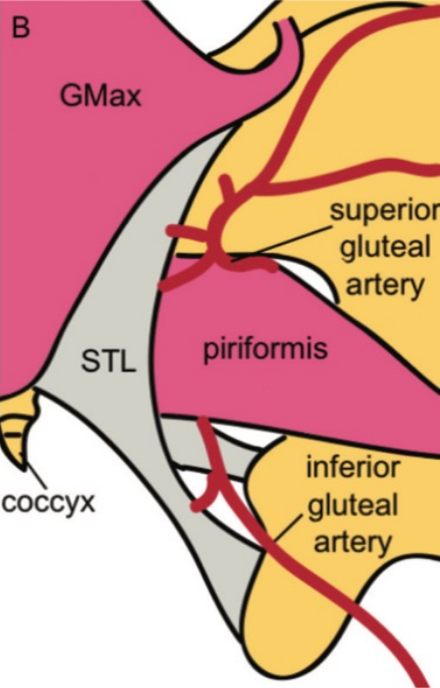
Boezaart AP. *The anatomical foundations of regional anesthesia and acute pain medicine*. UAE: Bentham Scientific Publishers 2016

N^o 2

Vaskularisering: Art. Sacroiliacale

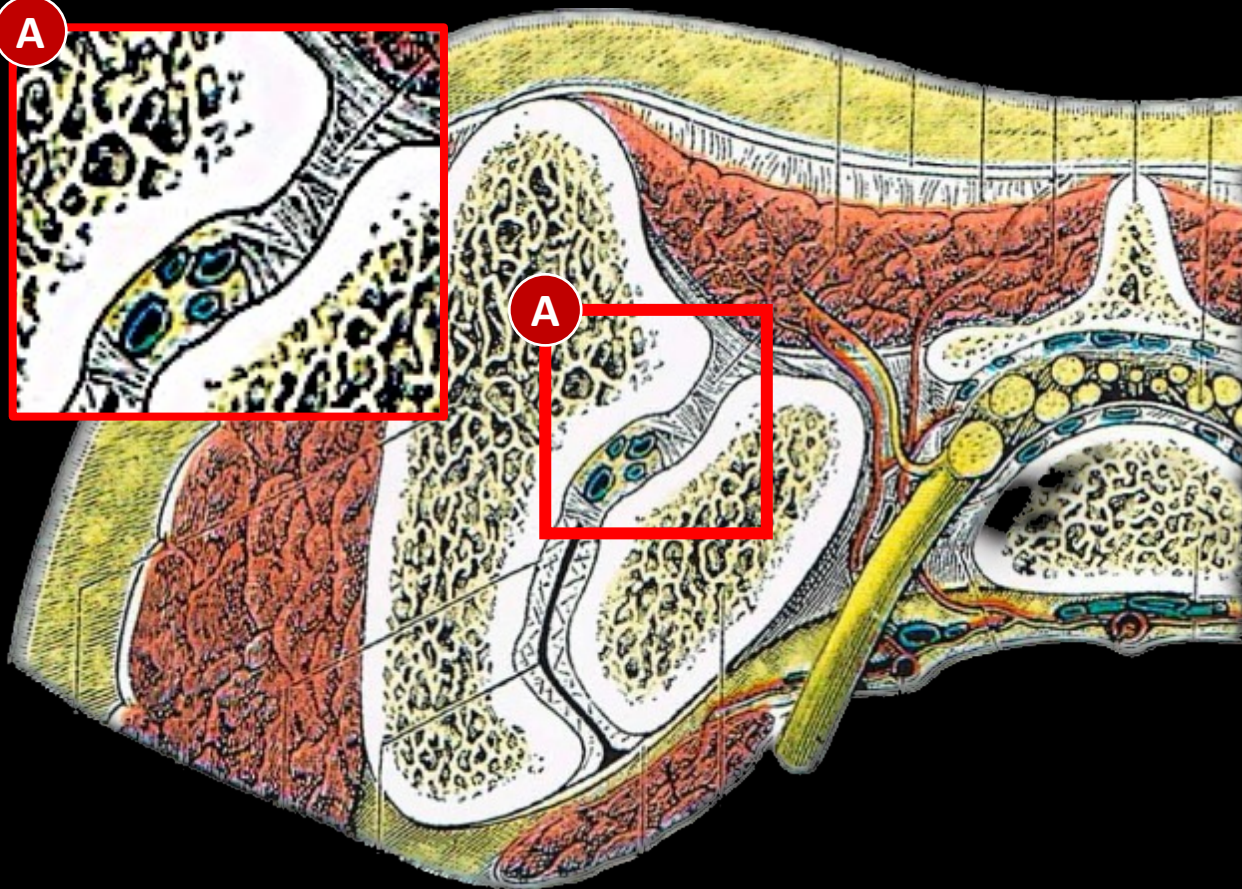


Arteriell Forsyning



Esses SI, Botsford DJ, Huler RJ, Rauschnig W. Surgical anatomy of the sacrum. A guide for rational screw fixation. *Spine (Phila Pa 1976)* 1991; 16:S283-288

Zoccali C, Skoch J, Patel A et al. The surgical neurovascular anatomy relating to partial and complete sacral and sacroiliac re- sections: A cadaveric, anatomic study. *Eur Spine J* 2015; 24:1109-1113



Vær oppmerksom på:

- Sterke, uutholdelige, tidvis invalidiserende unilaterale smerter
- Redusert allmentilstand (inkludert feber)
- Tidligere infeksjoner hud, knokler eller urogenitalsystem
- Nylige besøk hos tannlege
- Immunosuppresiv eller IV – stoffmisbruk
- Varme og hevelse over det affiserte leddet
- Positive SI provokasjonstester og smerte i SI ledd ved SLR

- Hematogen spredning av bakteriell og pyogen infeksjon til SI leddet fra andre regioner og systemer i kroppen er fullt mulig gjennom det venøse systemet
- Batson's Plexus
 - Systemisk
 - Reservoir
 - Treg flyt
- Bakteriemi under svangerskap
- Selv om forekomst er lav er svangerskap en risiko for sekundære infeksjoner i SI leddet

